

Wound Debridement

PhD, MD, professor

Viorel Nacu

Department of Operative Surgery and
Topographical Anatomy

Mechanism of Injury:

By Shear (forfecare), **sharp** - Low energy; Minimal cell damage; Straight edges, low contamination, Good Healing.

Compressive Forces - from blunt objects (Laceration, stellate or complex; ragged or shredded (tocate) edges; Higher possibility for infection

By Tensile (prin tractiune) (Triangular wound; Flap wound; More possibility to infection and marginal necrosis)

Wound debridement Goals

-
- ✦ Hemostasis
 - ✦ Cleaning from necrotic tissue Promote wound healing
 - ✦ Minimize scar formation

Anesthesia



Local

- ◆ Direct infiltration
- ◆ **Regional Block**
 - ◆ Smaller amount of anesthesia required
- ◆ **General anesthesia**

Examination

Remove obstructions: rings, clothing, other jewelry.

- ✦ Size
- ✦ Shape
- ✦ Margins
- ✦ Depth
- ✦ Underlying structures injury: tendons, nerves, vessels, muscles.
- ✦ Foreign bodies removal (Imaging)
- ✦ Open fracture

Wound Debridement

-
- ✦ Removes foreign bodies and devitalized tissue
 - ✦ Wound Irrigation
 - ✦ Creates sharp wound edges
 - ✦ Respect skin lines

Wound Closure

✦ Primary closure

- ◆ Suture, staple, adhesive, or tape
- ◆ Performed on recently sustained lacerations: <12 hours generally and <24 hours on face

✦ Secondary closure in case of possible infection

- ◆ Secondary intent
- ◆ Allowed to granulate

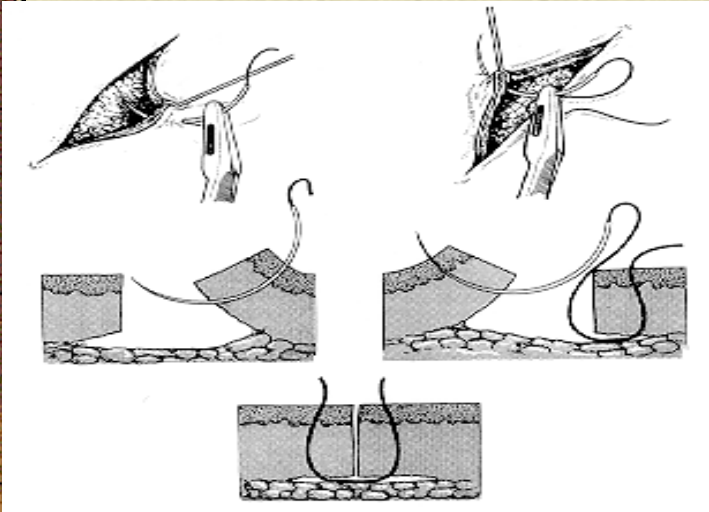
✦ Tertiary closure

- ◆ Delayed primary (observed for 4-5 days)

✦ Simple Interrupted suture

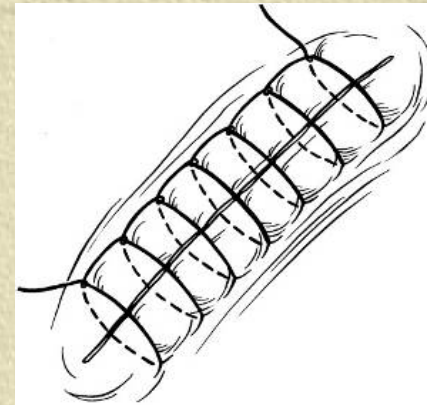
✦ Used on majority of wounds

✦ Each stitch is independent

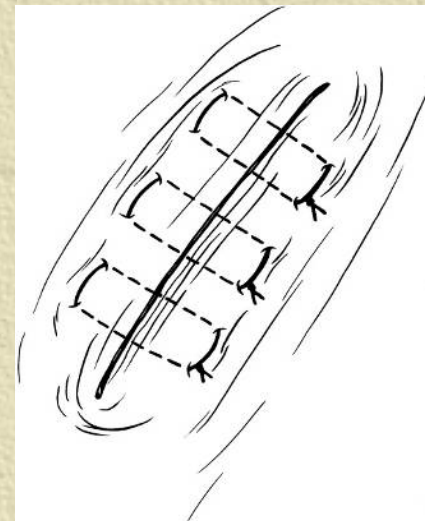
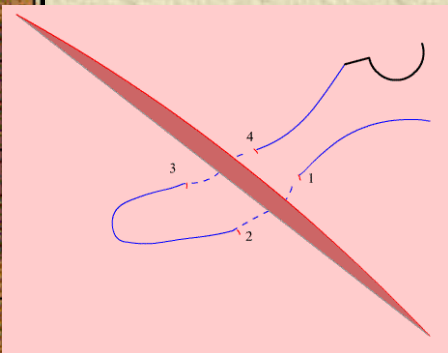


• Simple Continuous suture

- Rapid
- Easy removal
- Provides effective hemostasis
- ~~Distributed tension evenly along length~~
- Can also be locked with each stitch




Horizontal Mattress (single-layer closure)






“Bone and Jont surgery”

**PhD, MD, MPH, professor
Viorel Nacu**



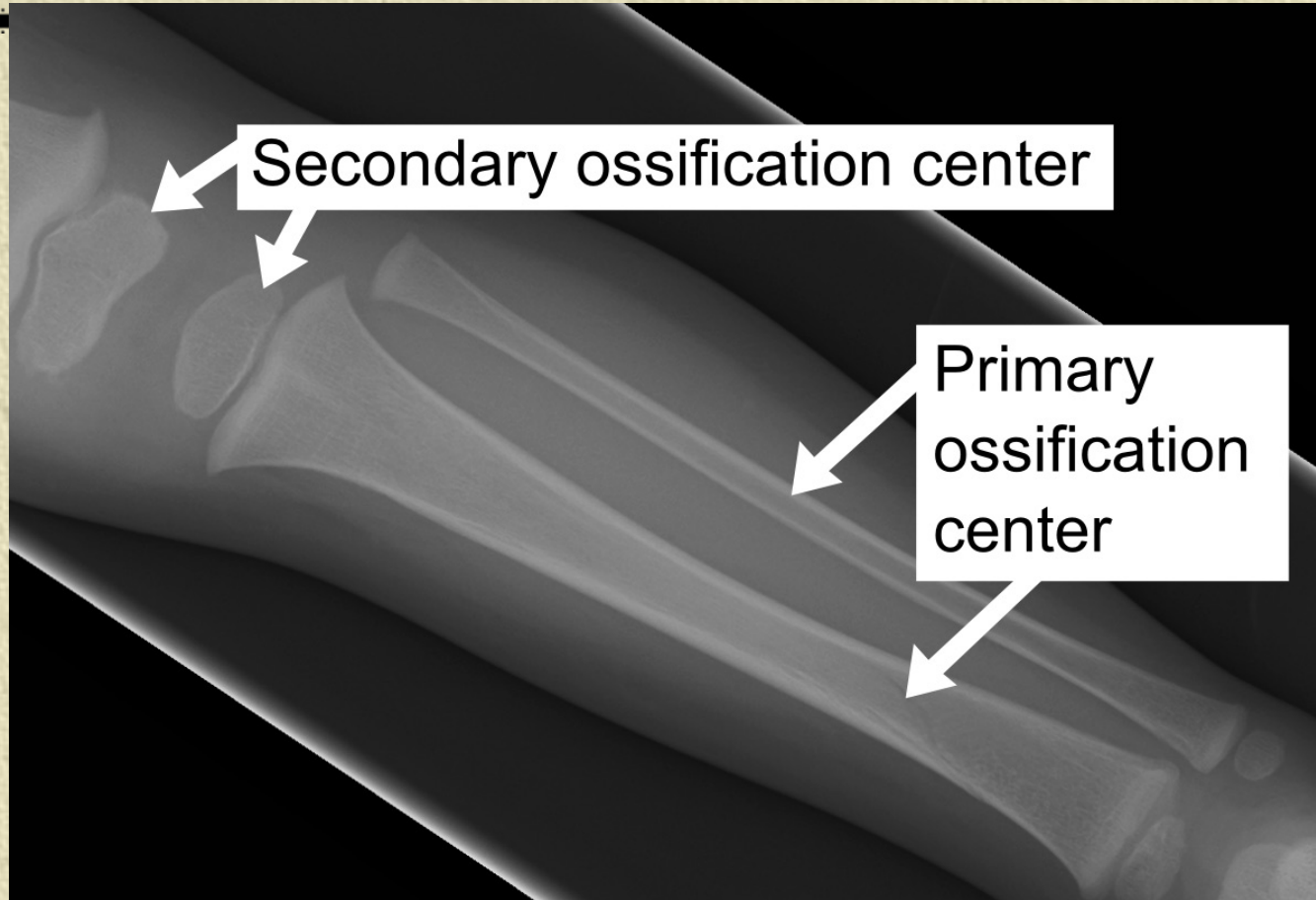
The traumatism of the skeleton borrows (occupies) one of the first places in structure of diseases requiring urgent surgical intervention.




THE PARTICULARITY OF the blood supply of the long bones.

For the newborn the arterial system is divided into few sites (diaphysis; methaphysis; epiphysis) till the teenage, when there are communications (connections) between these vessels

In children's is there important do not damage (injure) the ossification centers.



Skeleton Surgery :



- 1. Bones Surgery**
- 2. Joint Surgery**

Bone surgery:

- **Skeletal pin traction**


- **Osteosintesis**

- **Osteotomy**

- **Bone resection**

- **Bone grafting**

- **Sequestrectomy**



Osteosintesis – is the fracture reduction performed by open or closed technique.

Closed techniques - involve traction, plaster casts or splint


Open techniques – involve surgical application of hardware to secure fixation of the bone fragments.

The methods of osteosynthesis:

Internal fixation - Open reduction internal fixation is a method of surgically repairing a fractured bone. Generally, this involves either the use of plates and screws or an intramedullary (IM) rod, nail to stabilize the bone.

The open osteosynthesis


-
- When the skin is sectioned at the place of fracture. The closed osteosynthesis - when fixing agents are entered above or below a place of fracture and the place of fracture is not opening.




Lack of osteosynthesis -
necessity of removal of fixing
agents, researches of the
biodegradable fixing agents.

Bone Fixation:

External



Internal



External fixation is a method of immobilizing bones to allow a fracture to heal.

External fixation is accomplished by placing pins or screws into the bone on both sides of the fracture.

The pins are then secured together outside the skin with clamps and rods. The clamps and rods are known as the "external frame."

Advantages of external fixation are that it is quickly and easily applied.

The risk of infection at the site of the fracture is minimal, but there is a risk of infection where the pins are inserted from the skin into the bone.

✦ **Surgical Technique Ilizarov Circular wire fixators: - positioning**

✦ **reduction:** - traction will usually achieve an approximate reduction;

✦ **application of frame:** - - - - -

✦ - open the frame on one side (like a book) and place around the leg;

✦ - coupling bolts are aligned parallel to the crest of tibia;

✦ - ensure that there is proper clearance with at least one fingerbreadth of space anteriorly and two finger breadth of clearance posteriorly;


✦ **- coronal wires and frame attachment:**


✦ - wire is placed at level of & parallel to knee joint and marked;
- a wire is then placed approx one cm below joint line and marked;

✦ **- distal coronal plane wire:** - a wire is placed transverse to ankle joint and marked;

- the distal wire is driven across the fracture site

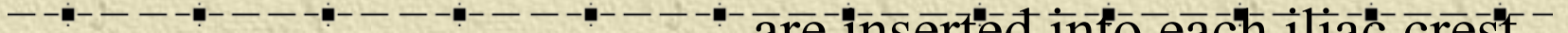
Internal fixation





Serclage wires. Having passed this device round the shaft of the bone and then twist the ends up firmly with one of the several forms of wire-twister which are available.


Pelvic fixator used for pelvic fractures, particularly those of the open book type. Three pins are inserted into each iliac crest and attached to metal rods used to “close” the open book injury



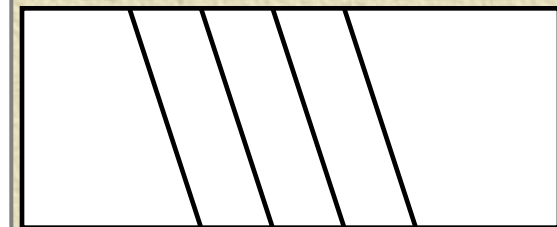
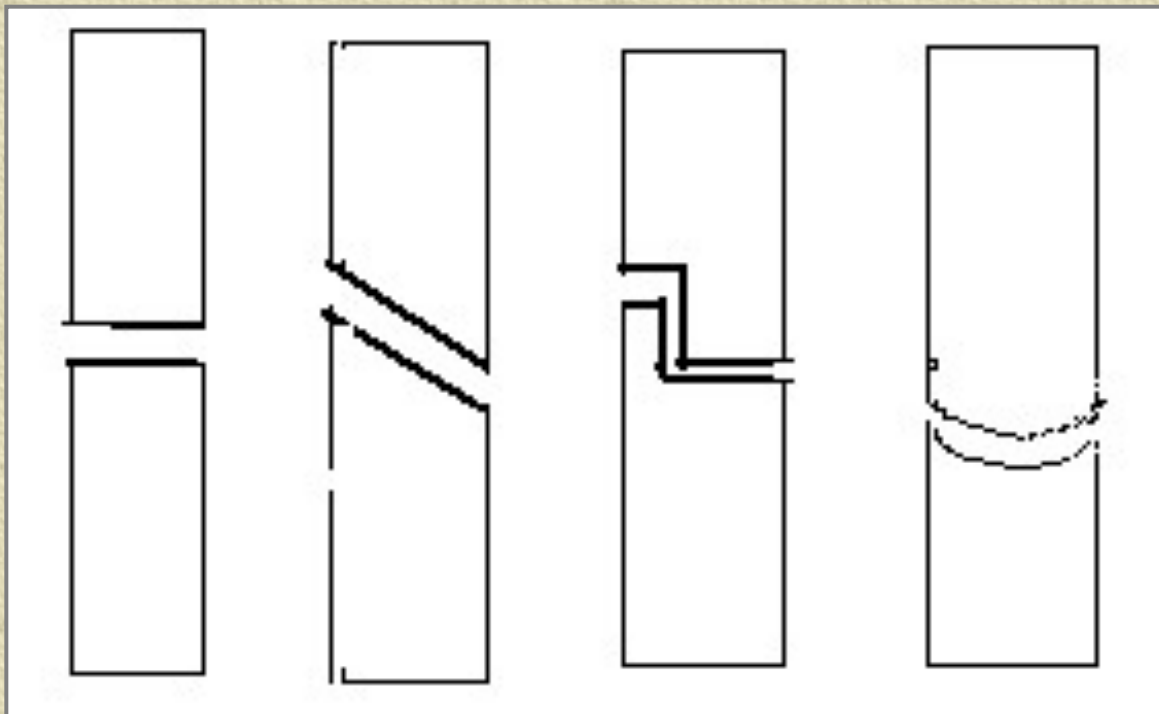
Medullary nails (rods) - (Kuntscher 1940, Bogdanov)

- used for the long bones such as the femur or humerus. It can be inserted by opening then on
- ~~driving the nail first up the proximal fragment and~~
- then down across the fracture after the fragments have been placed end to end or closed

Osteotomy – cutting of the bone.




The types of the osteotomy



♣ **Bone Resection** – cutting off the parts of bone.

On techniques of performance distinguish:

- *under periosteally*
- *transperiosteally*
- *Partial*
- *Total*



♣ **Bone grafting** is the procedure of transplanting bone from a donor area to a recipient area. The technique consists of placing live bone pieces in close contact with a healthy raw bone surface to stimulate growth of bone tissue in the new area.

Indications:

- 1. In the treatment of non-union of fractures.**
- 2. For filling cavities in bone.**
- 3. For bridging gaps in the shafts of bones caused by trauma, infection or excision of tumour.**
- 4. In the surgical fusion (arthrodesis) of joints.**

✦ Types of Bone grafts

✦ The bone used for grafting may be obtained from a donor site from

✦ **a) autogenous graft** - the same person (rib, the fibula, a part of femur, tibia or Ilium). It can be free or vascularized.

✦ **b) homogenous graft or allograft** a different person (isograft – transplant between a genetically identical pair (monozygotic twins))

✦ **c) heterogenous xenograft** - a different species transplantation between species, like calf or pig.

✦ **d) regenerative medicine** - tissue engineering, cells therapy, gene therapy.



✦ The best is the autogenous graft but it is difficult to get enough bone for use in children. In such cases, the maternal homogenous graft is the best alternative source.

✦ *Cadaver bone*, stored in Tissue Banks is extensively used not only to fill gaps but also to replace diseased ends of long bone or even total joints.

✦ In terms of anatomical types, the graft may be:

✦ *Cortical* bone graft in various shapes or *Cancellous* bone pieces.

✦ The cancellous bone is more osteogenic as its vascularisation is quicker and bone induction better. The cortical bone functions as a fixation device and cancellous bone promotes osteogenesis.

Vascularised bone graft

The success and the rate of integration of the bone graft with the recipient site is vastly improved when the blood supply is retained. This has been achieved by removing the graft with a vascular pedicle. This procedure requires the anastomosis of the vessels by *microsurgical* methods in addition to the fixation of the bone. This is used mostly while using fibula or rib as a graft.

Bone Bank

With increasing use of bone grafting procedures for various conditions, the need for large quantities of bone is great. This is met by storing bone in bone banks with special techniques of storage in sterile and viable condition.

Bone grafting operations

The type of bone grafting procedure depends on the biological and mechanical situation in a particular case.

- .

♣ **Sequestrectomy** – it's perform in case of

chronic osteomyelitis. An elliptical incision is used to excise adherent skin with sinuses. All dead bone on this subcutaneous surface is removed by lifting a window of cortex with sinuses and adherent skin attached. Surgical treatment will only succeed if all infected tissue and all dead bone are removed. The coverage is obtained with muscle pedicle grafts and adequate bone reconstruction.



Joints Surgery



Arthrocentesis (Joint Puncture),

Arthrotomy,

Arthrodesis,


Arthrolysis,

Arthroplasty,

Joint resection,

Arthroscopy

Puncture of the Joint



diagnostic




therapeutic

Aspiration of the knee joint:

when the knee joint is infected, inflamed or there are hemarthrosis, the amount of synovial fluid may increase. Fullness of the thigh in the region of the suprapatellar bursa may indicate increase in syn. Fluid. The bursa can be aspirated to remove the fluid

Arthrotomie - it's the opening of the joint.



Joint Resection

Indications - on trauma; tumors; tuberculosis; aseptic necrosis. It can be partial o total.




Arthrodesis - operation directed on creation of an immovability in a joint in functional favorable position. Indications: arthritis with the expressed painful syndrome, **dangling joints after a poliomyelitis, chronic dislocations.**




This operation is carried out only exceptionally nowadays. In this operation, the surgeon removes all joint surfaces up to the raw bone and then presses and fixes the denuded joint surfaces together with special plates and screws. Healing of the arthrodesis - solidifying of the bone tissue and obliteration of the previous joint space - takes about 12 weeks.

Arthrolysis – is removal (cutting) of the intrarticular adhesences.




Arthroplasty - It is directed on restoration of mobility in joint by formation of articulate surfaces. It can be by plasties whth fascies, skin or cartilage grafts.



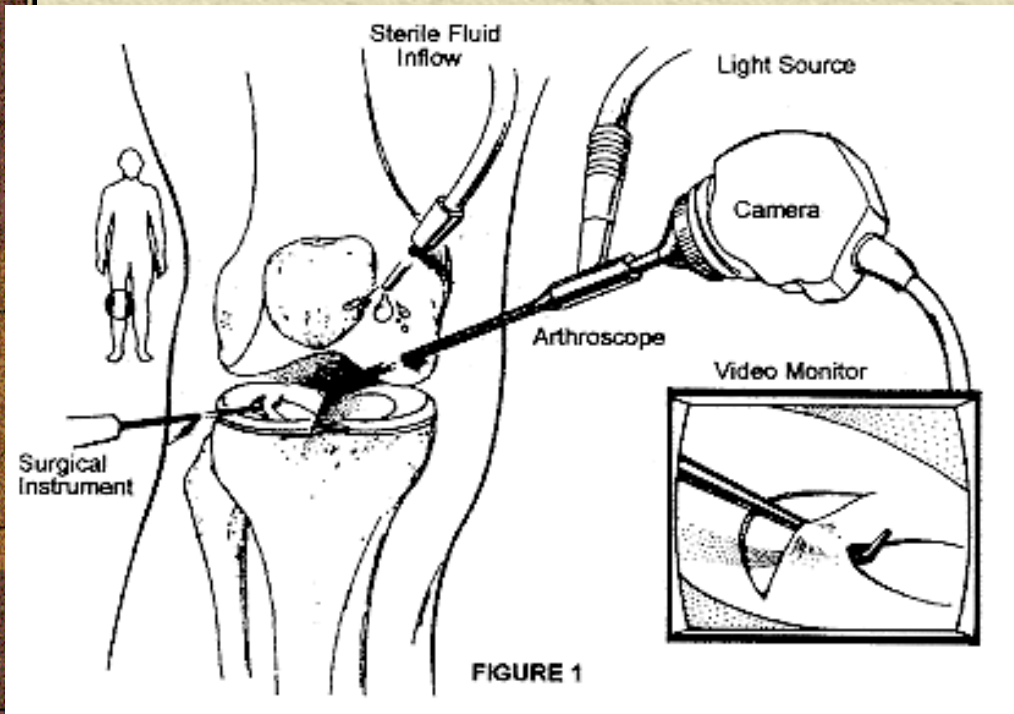
- Endoprosthesis - replacement of the damaged with an syntetic on.


The destroyed joint surfaces are resected and precisely replaced by prosthetic implants. These implants are fixed either cementless or with bone cement. There are different types of prostheses available like unicondylar or totalcondylar prosthesis.

For the implantation of these modern prosthesis only a very small bone resection is necessary. The main ligamentous structures like collateral ligaments and posterior cruciate ligament (PCL) are spared. There is always a component for the femoral and the tibial part, whereas the replacement of the patellar surface is not necessary in most of the cases.




Arthroscopy Surgical access on the hip and knee. The arthroscope is introduced into the the knee joint through a small stab incision and allows examination of structure inside the knee without major surgical exploration.







Joint resection – partial and total



Amputation
and
dezarticulation






- In the United States there are approximately 150000 amputations performed annually.


- an estimated 2.5 million amputees living in North America alone.

- Ischemia from vascular disease, usually as complications from diabetes, is the most common cause of amputation. Only 3% of the U.S. population is afflicted by diabetes, however diabetics make up 51% of the total amputations performed annually.



- The other 50 % of amputations are caused by massive trauma, infection, or tumors. These causes are more frequent in people under the age of 45.

- 50 % of the estimated amputees in North America are between the ages of 21 and 65.



The amputation is the surgical manipulation including the removal of the distal part of the limb by bone or bones section (cutting).

Disarticulations is removal of the distal part of the limb through the articulation without bone section.

Disarticulation in the Lisfranc articulation

Dezarticulation in the coxo-femorale articulation

The goal of the amputation and disarticulation is to solve the patients life.

The indication:

- 1. ischemic or infective gangrene,**
- 2. diabetes mellitus,**
- 3. trauma,**



4. Osteomyelitis,

5. Anaerobic infections,

6. Tumors,


7. Frostbite. - - - - -

Upper limb amputations can be:

- Digital
- Forearm
- Through elbow
- Above elbow
- Forequarter

Lower limb amputations can be of the:

- Toe



- Transmetatarsal


- Syme's

- Below knee

- Through knee / Gritti-Stokes

- Above knee

- Hindquarter (hemipelvectomy)



Reamputation - in case of the disease progress or in the vicious stump what can not be prosthised.

The amputation include 3 steps:

- **I. The cutting of the soft tissue;**
- **II. The cutting of the bone;**
- **III. The ligation of the vessels, the nerve cutting, haemostasis and stump forming.**

Amputation

- ✦ **Surgical amputation**

- ✦ **Traumatic amputation**

- ✦ **Levels of amputation**

- ✦ **Complications of amputations:**
hemorrhage, infection, phantom limb pain, problems associated with immobility, neuroma, flexion contracture.

- ✦ **Rehabilitation**

- ✦ **Nursing Management**



The goal of surgery

**should be the creation of a
dynamically balanced residual
limb with good motor control
and sensation.**

Bone section

The periosteum is divided circumferentially at the same point in order to prevent it from being stripped, and the bone is cutted with a Gigli saw.

The sciatic nerve is gently pulled down and its epineurium is held with forceps while the arterial nerve ischiadici is caught and legated. The anesthetic solution is injected under epineurium, after that the nerve cutting is provided 5-6 cm above the bone end.

Haemostasis is secured.

The cutted end of the femoral bone is rounded with a rasp and a slight bevel is produced over the anterolateral aspect.

The Amputation can be:

a) With one flap

b) ~~With two flaps.~~

By the structure, the flaps can be:

1. fascioplactic;
2. tendoplactic;
3. mioplactic (suture of the antagonists muscles);
4. periostoplactic;
5. Osteoplastice (the Syme)

Level of Amputation is **Influenced by:**

1. Cosmetic appearance;

2. Functional requirement;

3. Comfort ;

4. Viability of soft tissues

Amputation should be performed at the level at which healing is most likely to be complete.


But which will also permit the most efficient use of the limb following rehabilitation and ease in walking that can be achieved with a distal amputation.

As long a limb as possible should be preserved, in order to maintain the most nearly normal ambulation with the least energy expenditure.

Compared with normal walking, energy expenditure is increased 10-49% with a below/knee prosthesis, 50-70% with an above-knee prosthesis, and 60% with crutches.




 **The features in
amputations on childrens
limb**



✦ 1. Growth of the soft tissues is less than of the bones, this fact brings to formation of the conic stump .


To prevent this it is necessary to create drift of soft tissue above bone, thus considerate the skin contracture at children than at an old person.

Sewing together the antagonists muscles as a prophylactics or the conic stump.




✦ 2. Pair bones of a leg (shin) and a forearm non-uniformly grow. Outstrips growth the peroneal and radial bones.

✦ These bones have to be cutting shorter by 3-4 cm than tibial and ulnar bones.



✦ 3. At children static deformation of bones stump more often is observed.

- 
- ✦ 4. Amputation of the lower limb in children results in deformation and atrophies of a corresponding half of basin,
 - ✦ the amputation of the upper limb results in deformation of a humeral belt, sometimes a curvature of a spine column is also deformed.

Complications of amputation

-
- **Nonhealing**
 - **Infection**
 - **skin necrosis**
 - **pain and flexion Contracture**
 - **Neuroma – in a stump** can be treated by injection of a local anesthetic or excision of the neuroma.

• Phantom limb pain –

is the sensation that a painful limb is present after amputation. Hypotheses concerning etiology include the **gate theory** (loss of sensory input decreases self-sustaining neural activity of the gate causing pain);

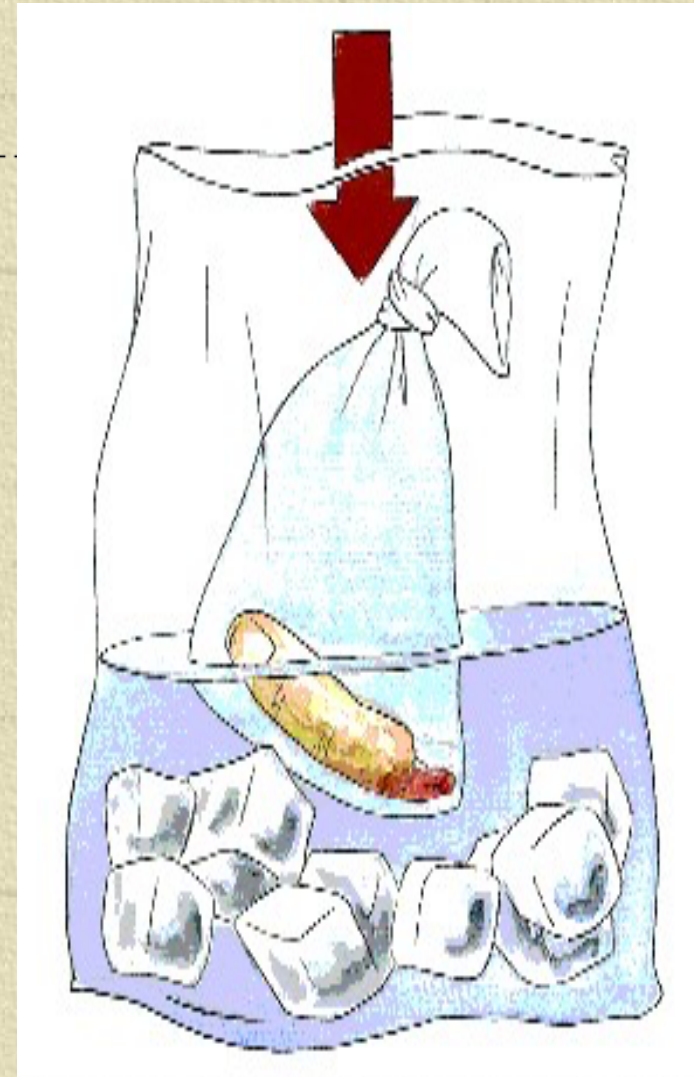
• **the peripheral theory** (nerve endings in the stump represent parts originally innervated by the severed nerve); **the psychological theory** (hostility, guilt and denial are interpreted as pain).

Microsurgery – techniques now allow previously hopeless cases of traumatic amputation to be treated by replantation.

Function following replantation of the palm, wrist, or forearm, is less satisfactory.


The advantages and disadvantages of amputation and replantation must be weighed:

with amputation, there is a cosmetic defect but a relatively short period of rehabilitation; with replantation, there is normal appearance but a long, costly rehabilitation period.




Prosthesis

Modern total-contact prostheses can be fitted satisfactorily on any properly constructed and well-healed lower extremity amputation stump, usually resulting in excellent function.



Innovations in amputation techniques and in care after surgery, especially the rigid dressing approach and the newer prosthetic techniques, including computer-assisted design and manufacturing of prosthetic sockets, have greatly altered the approach to surgery and rehabilitation. The amputation stump and its prosthesis must assume the walking and weight-bearing functions of the amputated limb.



Burgess has repeatedly pointed out that a strong and dynamic stump must be created that will function as a motor and sensory end organ. His concept of such a stump functioning as a foot like end organ with the prosthesis serving as the “shoe” on this “foot” is exciting and challenging.



Thanks for your
attention!