



# **The clinical anatomy of the Thorax**

**Dr. h., professor**

**Viorel Nacu**



## **The methods of Thorax examinations:**

- 1. Clinical (percussion, auscultation)**
- 2. CT**
- 3. X-ray**
- 4. USG**
- 5. ECG**
- 6. Endoscopic**



## THE BORDERS:

- *Superiorly clavicula*, stenum, acromions, spinous procesus of the 7-th vetebra C VII.
- *Inferiorly*: procesul xifoid, rig arch, borderline, the XII rib, to the spinous procesus of the Th XII vertebra.



# The landmarks:

- **Clavicles** The clavicles are visible and palpable bony structures located just below the neck.
- **Manubrium** of the sternum; suprasternal notch at the top of the manubrium. The superior vena cava passes behind the manubrium.
- **Sternal angle:** the level of the 2nd costal cartilages and corresponds to the level of the disc space between the 4th and 5th thoracic vertebrae.
- **Sternum:** The right border of the heart lies posterior to it.
- **Subcostal angle:** The subcostal angle is at the inferior portion of the sternum, between the 7th costal cartilages.
- **Costal margins:** The costal margins are formed by the medial portions of the 7th through 10th costal cartilages. They're easily palpable.

**Apex beat of the heart:** The apex beat of the heart is caused by the contractions of the heart as it beats. at the 5th intercostal space on the left side (the mitral area).



## Posterior chest wall

The spinous process for the 7th cervical vertebra.

The scapulae.

The superior angles at the top of the scapulae are at the level of the 2nd thoracic vertebrae.

The spines of the scapulae.

The medial border of scapula,

The inferior angle, is at the level of the 7th thoracic vertebra.

The posterior part of the thoracic cage can be distorted due to scoliosis or ankylosing spondylitis.



# The orientations imaginary lines

**Midsternal (anterior median) line:** Runs down the middle of the sternum

**Right and left midclavicular lines:** Run parallel with the midsternal line, passing through the midpoint of each clavicle

**Anterior axillary line** - along the anterior axillary fold, close to the front of the thorax

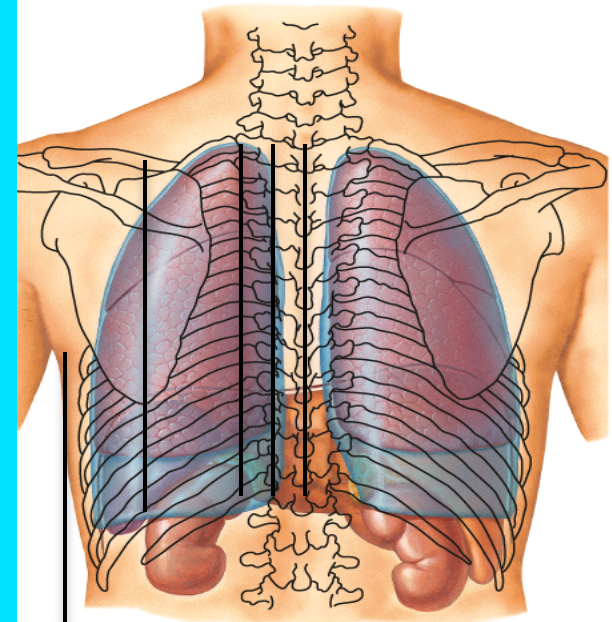
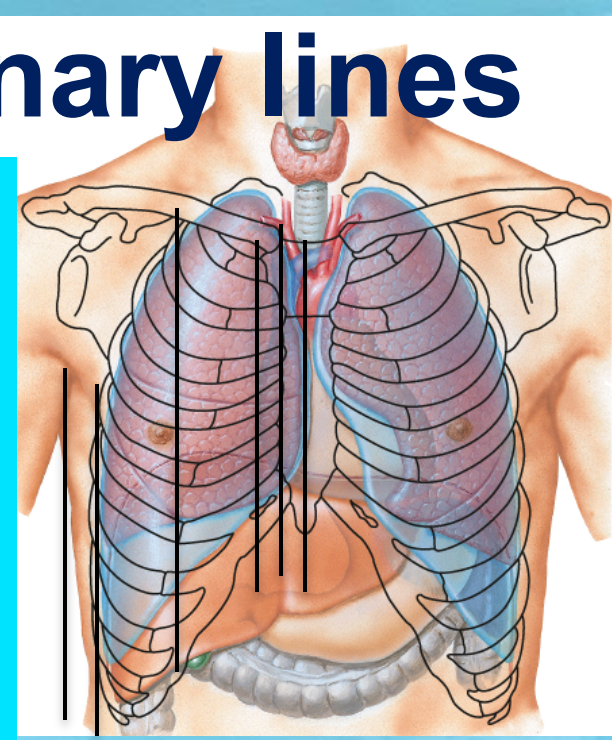
**Midaxillary line** - midway between the anterior and posterior axillary lines, starting from the deepest part of the axilla.


**Posterior axillary line** - along the posterior axillary fold.

**Scapular lines** - pass through the inferior angles of the scapulae

**Paravertebral line** – at the level of the processus transversus vertebra

**Midvertebral (posterior median) line:** Runs vertically down the midpoint of the spine





# The anomalies of the thorax

may occur as isolated problems, but are also seen in conjunction with other skeletal or organ anomalies.

- Among the most common thoracic osseous anomalies are:

**pectus excavatum,**

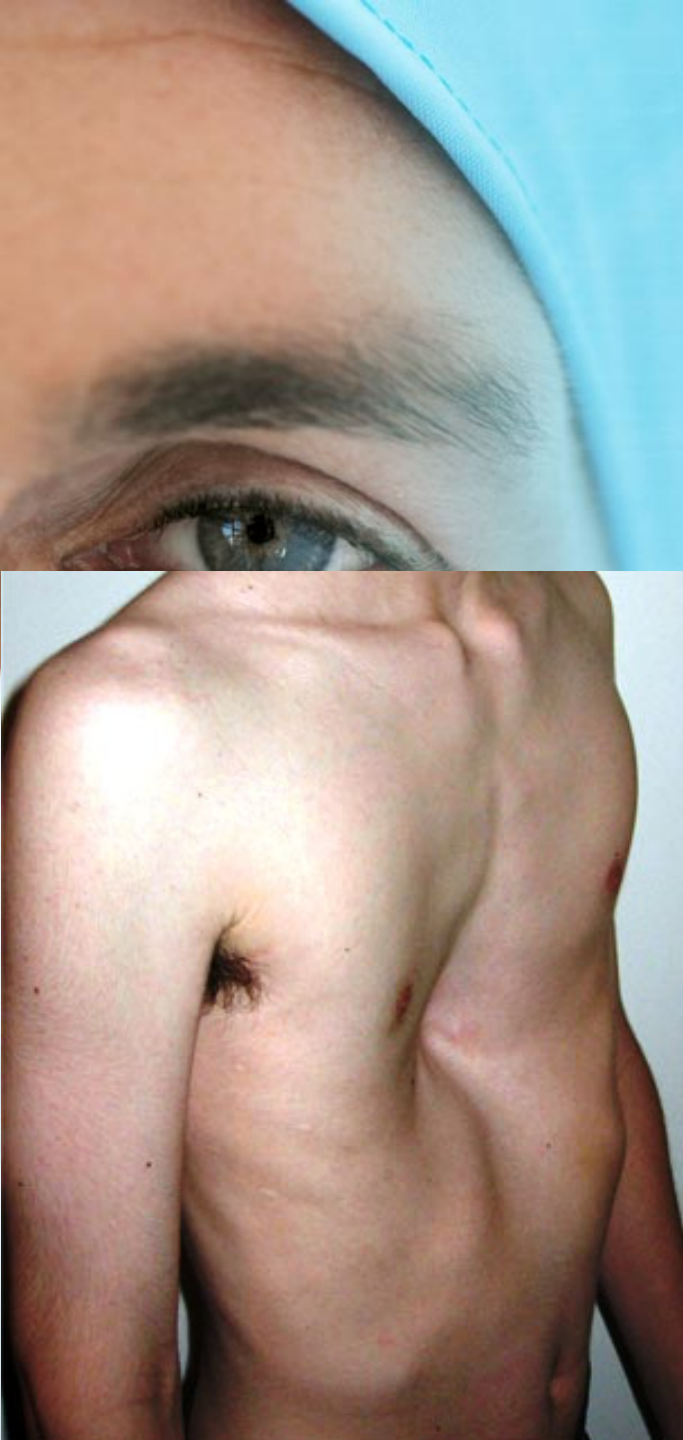**pectus carinatum,** sternal ossification abnormalities, and deformity of the spine, ribs, clavicle, or scapula.



## Pectus excavatum. More frequent in boys

**Pectus excavatum** - the sternum forms inward, creating a depression in the centre of the chest.

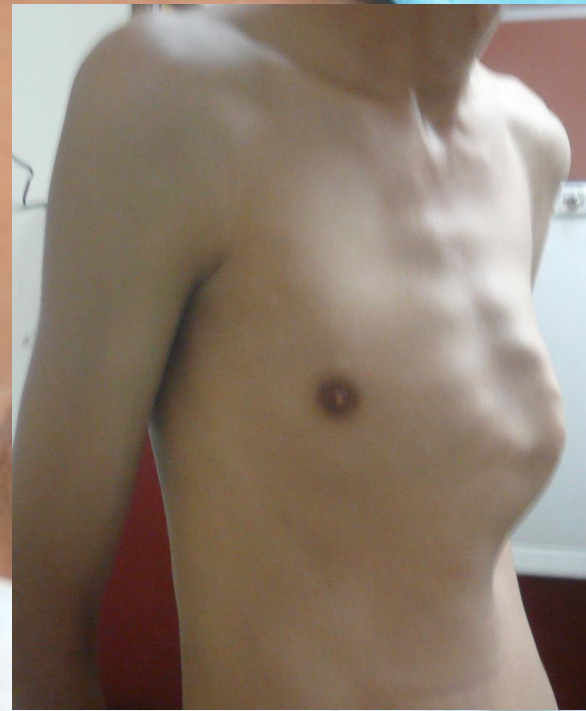Again, this condition may occur independently or in association with other syndromes (can affect normal organ development and function).

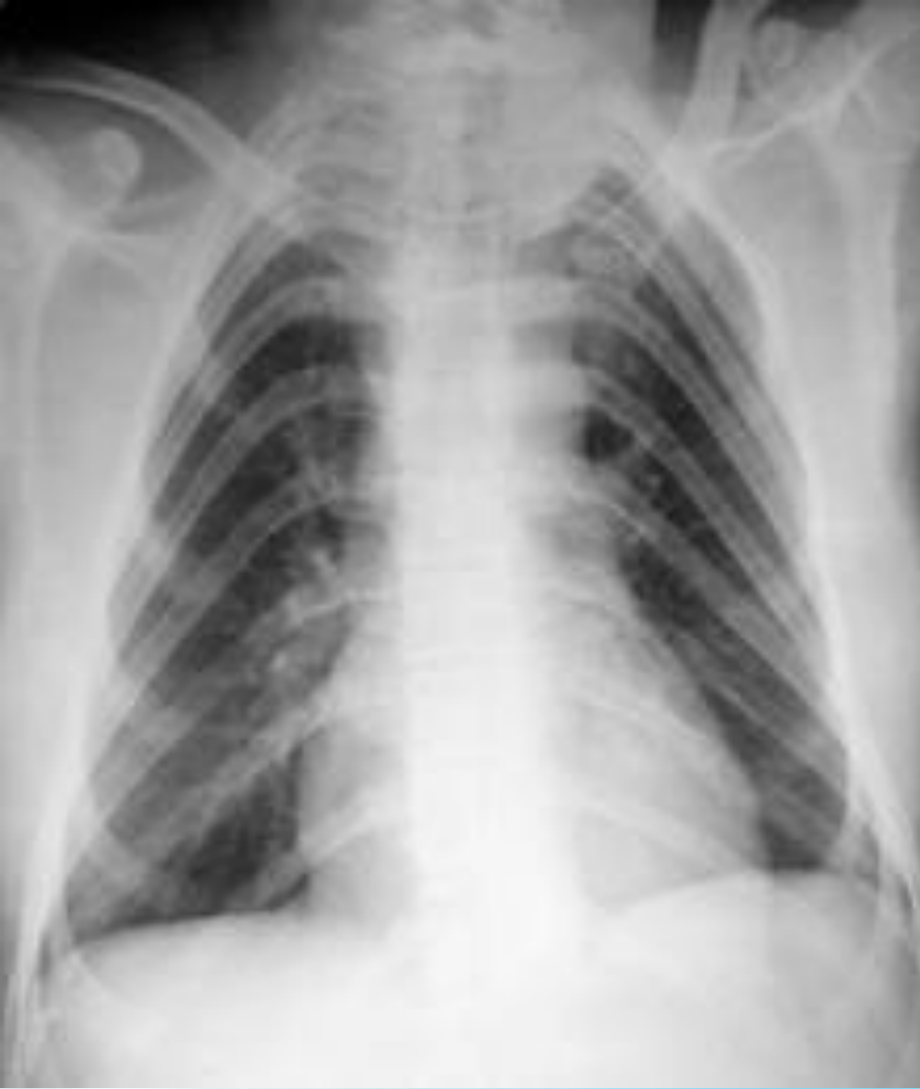



# Pectus carinatum,

Pectus carinatum is protrusion of the ribs and sternum anteriorly. This can occur independently or in association with other genetic disorders, including trisomy 18 or 21. There is little impact in development of vital organs.





The long, flat chest of patients with constitutional visceroptosis.

**Neurological diseases, pulmonary fibroses.**

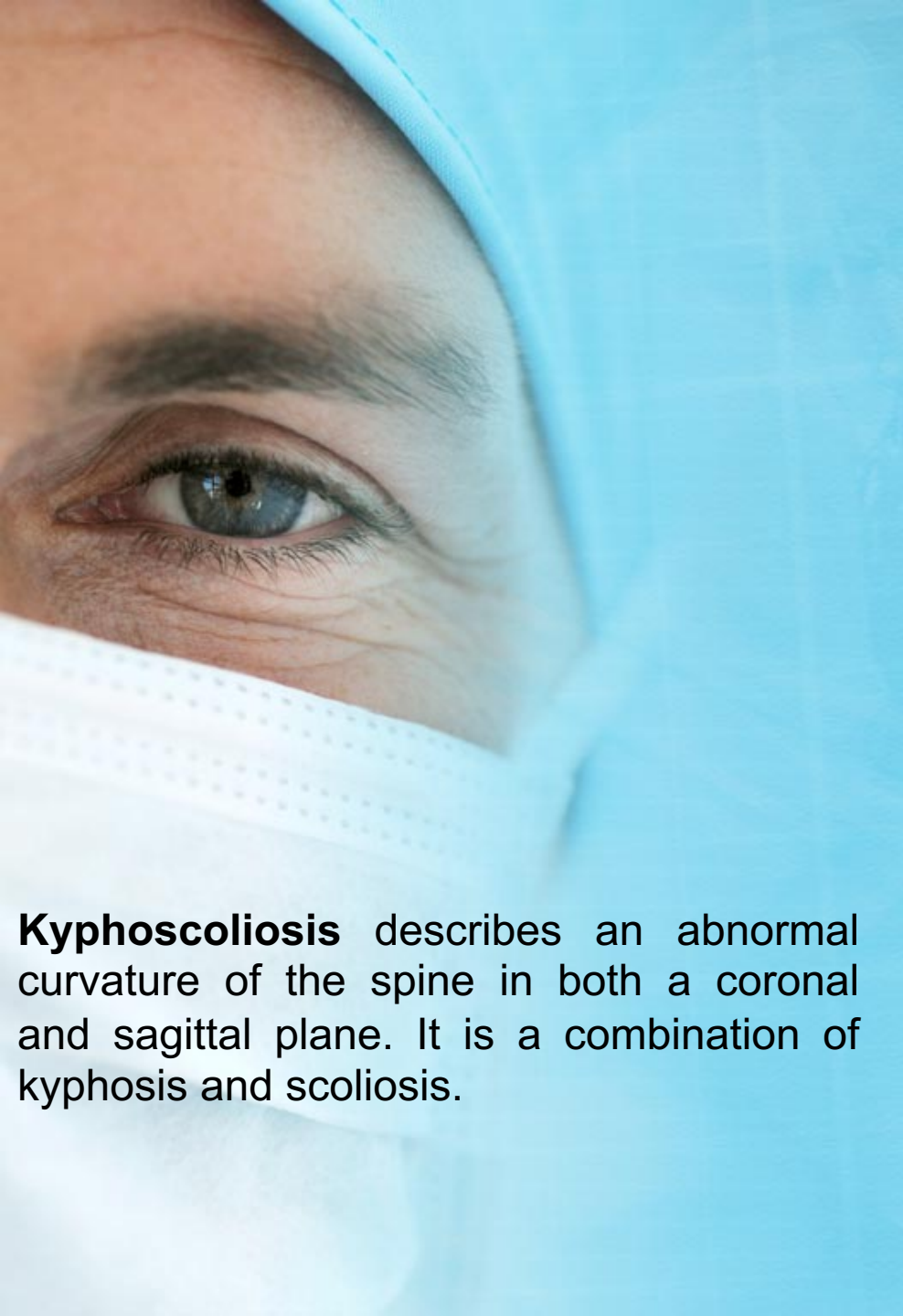
Toracele pare aplatizat, the ribs a verticalized, with narrow intercostal spaceS.



**Thorax emphysematous-pulmonary emphysema** in which the air sacs of the lungs are grossly enlarged, causing breathlessness and wheezing

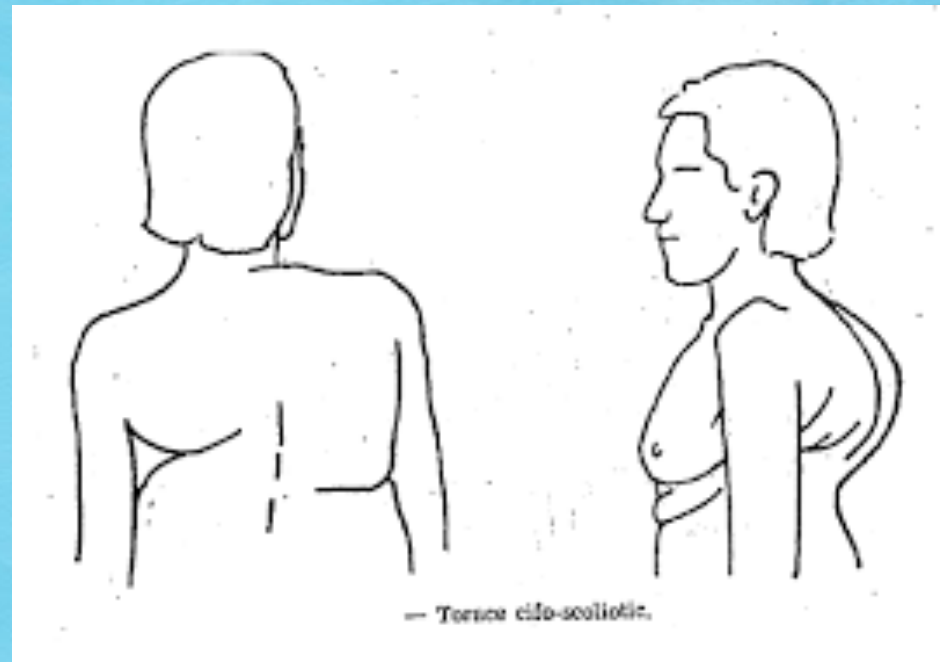
- All the thorax dimensions are higher:
- The ribs are horizontal;
- The diaphragm is flattened
- The heart is verticalised

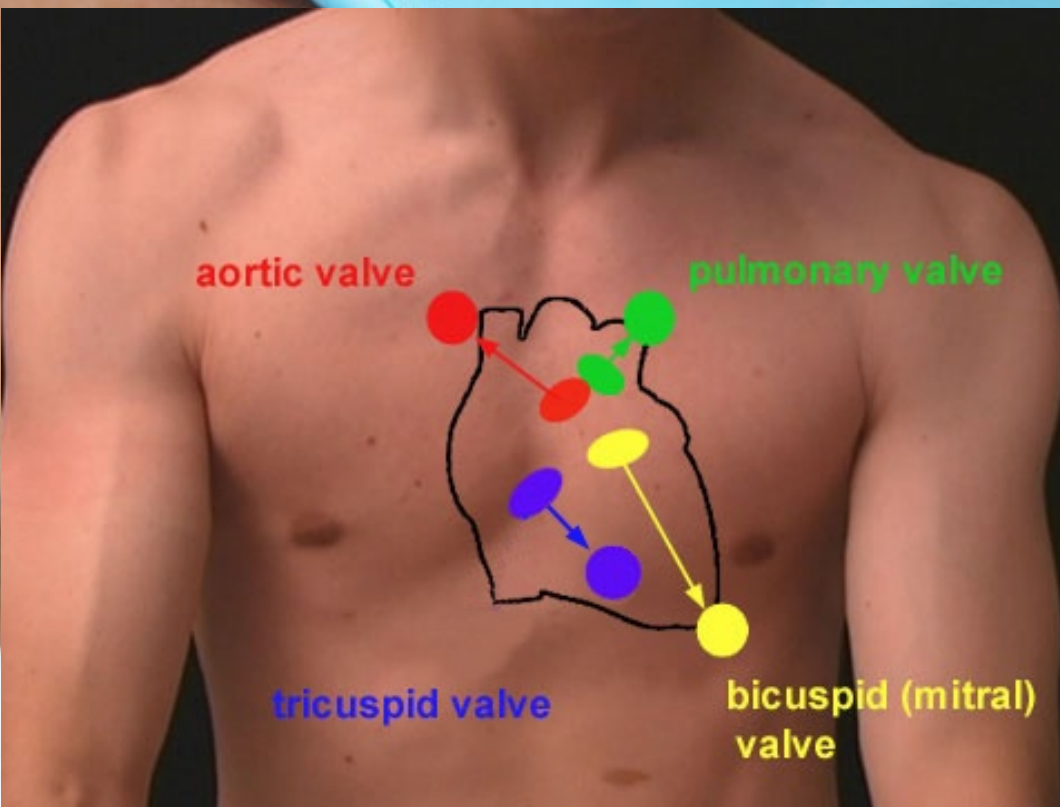




**Kiphosys:** refers to the abnormally excessive convex *kyphotic* curvature of the spine as it occurs in the thoracic

**Kyphoscoliosis** describes an abnormal curvature of the spine in both a coronal and sagittal plane. It is a combination of kyphosis and scoliosis.





**Near the sternum are four areas that are used for auscultation the heart**

**Aortic area:** At the 2nd intercostal space to the right of the sternum

**Pulmonic area:** At the 2nd intercostal space to the left of the sternum

**Tricuspid area:** Over the lower-left sternal border

**Mitral area:** At the left 5th intercostal space at the midclavicular line

# Layers:

1. SKIN
2. Subcutaneous fat tissue,
3. The superficial fascia (lig. Suspensorium mamma). Envelope the mammary gland.
4. The deep fascia, the superficial sheet:
  - anteriorly -m. pectoralis major ,
  - posteriorly -m. trapezius
  - m. serratus ant.
  - m. latissimus dorsi
5. the deep sheet of the deep fascia:
  - anteriorly - m. pectoralis minor
  - posteriorly - m. levator scapulae
  - mm. romboideus
  - m. seratus post. sup.
  - m. erector spinae
  - m. transversospinalis
6. The ribs and intercostal space;
7. Endotoracic fascia;
8. Parapleural space of conective tissue;
9. The parietal Pleura.





## **The thoracic inlet (superior thoracic aperture)**

**Formed by:**

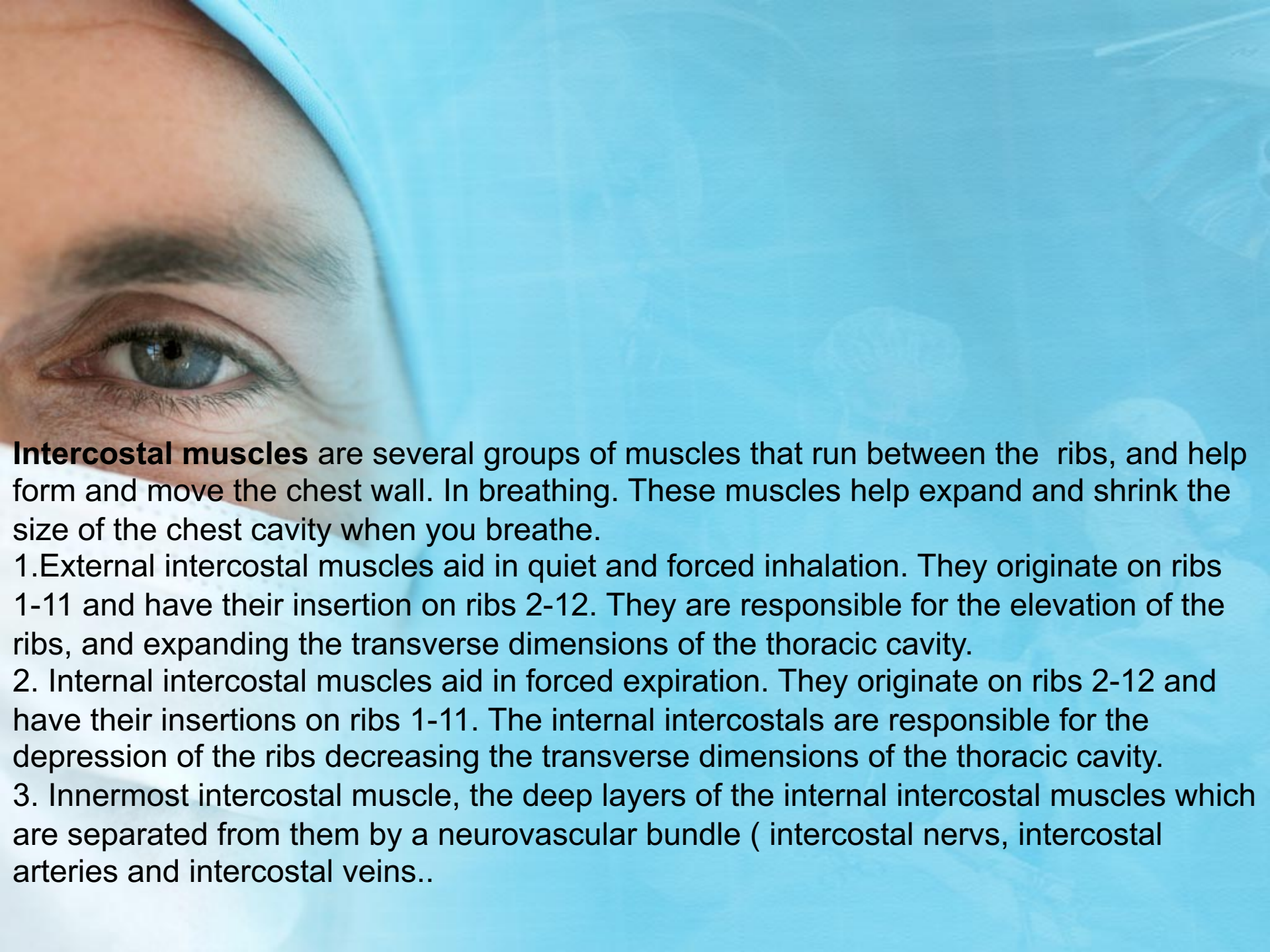
**o T1 (first thoracic vertebra) ; 1st ribs, Manubrium sternale**

***Contents*** Great vessels heading for neck and upper limb ; Common carotid artery; Internal jugular vein; Subclavian artery and vein (vein tends to be anterior to artery); Esophagus; Trachea; Nerves and lymphatic system; Also apex of the right lung is superior to the clavicle .

# The intercostal space

**The intercostal**

**space** is the space between two ribs (Lat. costa). Since there are 12 ribs on each side, there are 11 intercostal spaces, each numbered for the rib superior to it.

A close-up photograph of a person's eye, looking slightly to the left. The person is wearing a light blue surgical cap. The background is a solid light blue color.

**Intercostal muscles** are several groups of muscles that run between the ribs, and help form and move the chest wall. In breathing. These muscles help expand and shrink the size of the chest cavity when you breathe.

1. External intercostal muscles aid in quiet and forced inhalation. They originate on ribs 1-11 and have their insertion on ribs 2-12. They are responsible for the elevation of the ribs, and expanding the transverse dimensions of the thoracic cavity.

2. Internal intercostal muscles aid in forced expiration. They originate on ribs 2-12 and have their insertions on ribs 1-11. The internal intercostals are responsible for the depression of the ribs decreasing the transverse dimensions of the thoracic cavity.

3. Innermost intercostal muscle, the deep layers of the internal intercostal muscles which are separated from them by a neurovascular bundle ( intercostal nerves, intercostal arteries and intercostal veins..





Pleural Diseases & Signs:

## **Pleural Effusion**

From Daffner 1993

Right-sided pleural effusion

- Accumulation of fluid in the pleural space
- Transudative vs. exudative effusion
- Empyema as potential sequelae to exudative effusion

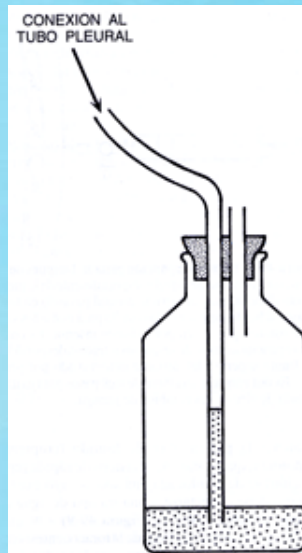
## Pleural Diseases & Signs:

### **Hemothorax** (Intrathoracic bleeding).

From Netter 1988

- Numerous sources of potential bleeds
- Large hemothorax: hypovolemic shock, restricted ipsilateral ventilation  
contralateral mediastinal shift

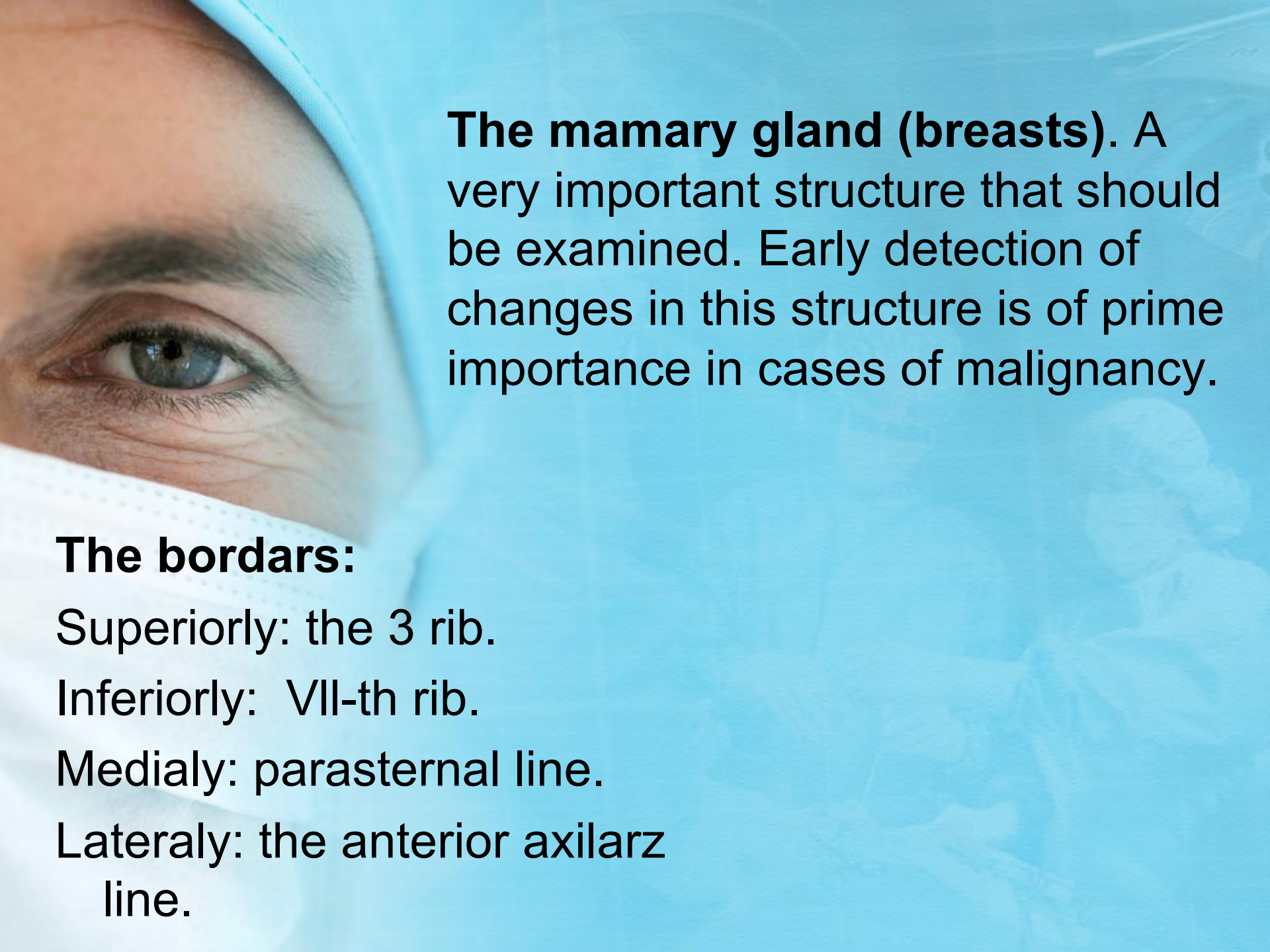
**A chylothorax** (or **chyle leak**) is a type of pleural effusion. It results from lymph called chyle accumulating in the pleural cavity due to either disruption or obstruction of the thoracic duct.





- **Thoracentesis** (Moore 87-88)
- -insertion of hypodermic needle through an intercostal space into pleural cavity. This is done to obtain a fluid sample or remove blood or pus from the cavity. When performing this procedure, you must avoid the (intercostal vein, artery, and nerve) so you must insert the needle just superior to the rib.





**The mammary gland (breasts).** A very important structure that should be examined. Early detection of changes in this structure is of prime importance in cases of malignancy.

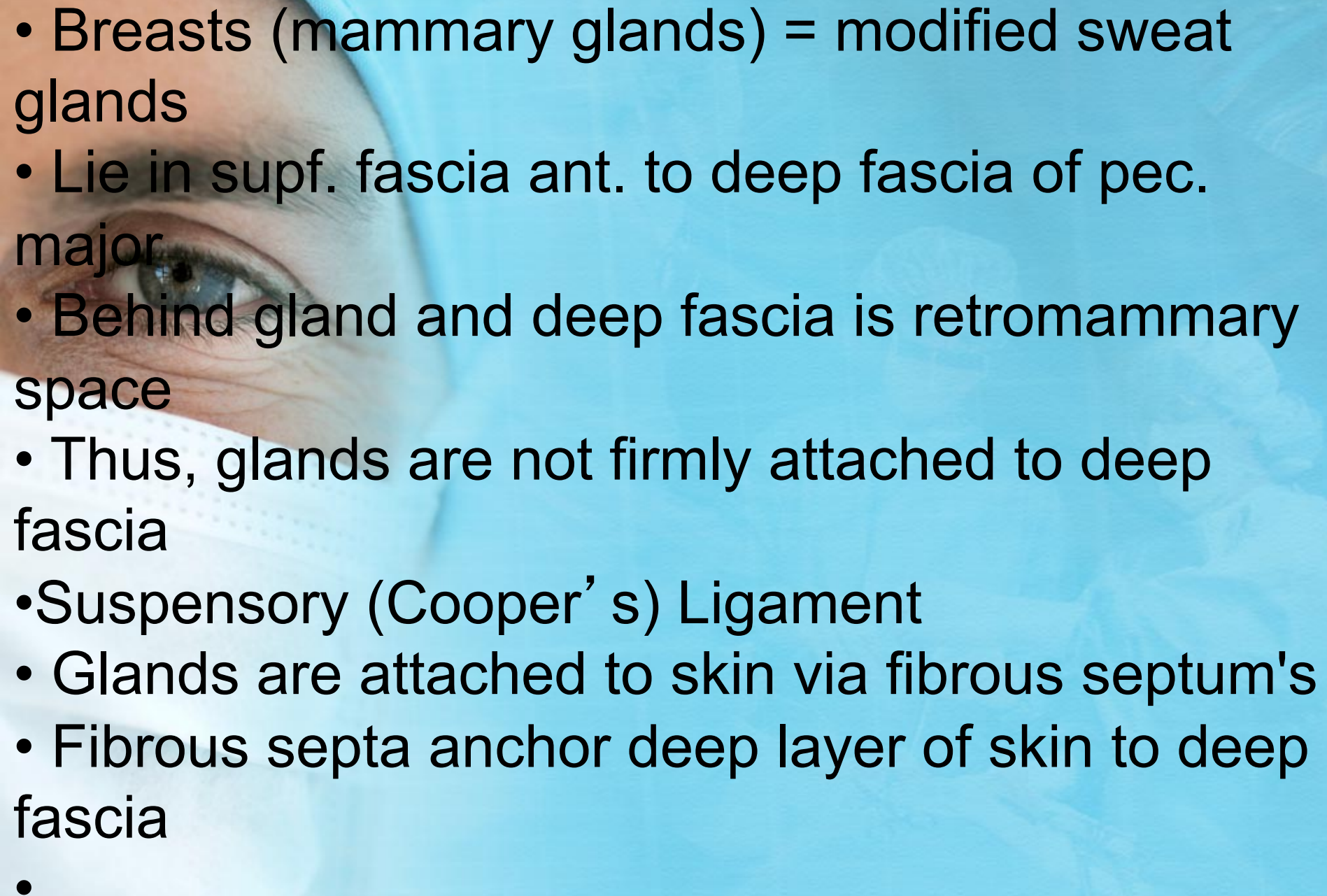
**The borders:**

Superiorly: the 3 rib.

Inferiorly: VII-th rib.

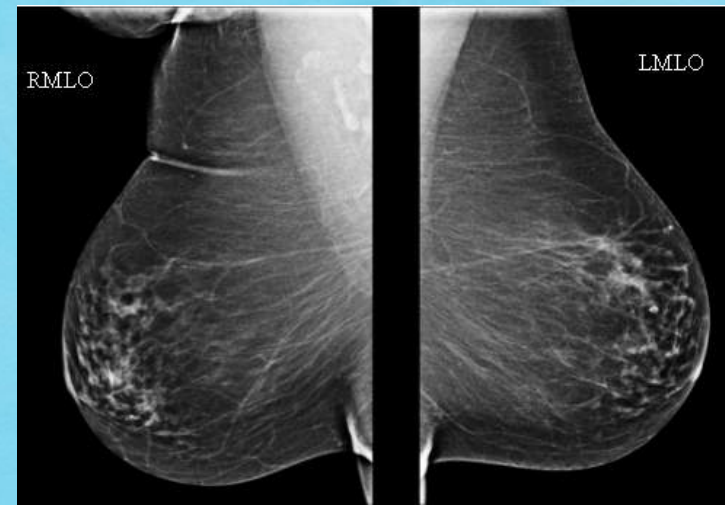
Medially: parasternal line.

Laterally: the anterior axillary line.

- 
- Breasts (mammary glands) = modified sweat glands
  - Lie in supf. fascia ant. to deep fascia of pec. major
  - Behind gland and deep fascia is retromammary space
  - Thus, glands are not firmly attached to deep fascia
  - Suspensory (Cooper's) Ligament
  - Glands are attached to skin via fibrous septum's
  - Fibrous septa anchor deep layer of skin to deep fascia
  -

## Structure of the Breast

- Compartmentalized fat bounded by fibrous septa;
- Glandular lobules drained by 15-20 lactiferous ducts
- Lactiferous ducts converge & open onto nipple;
- Areola surrounds nipple & contain sebaceous glands
- (i.e., produce lubrication for nipple)







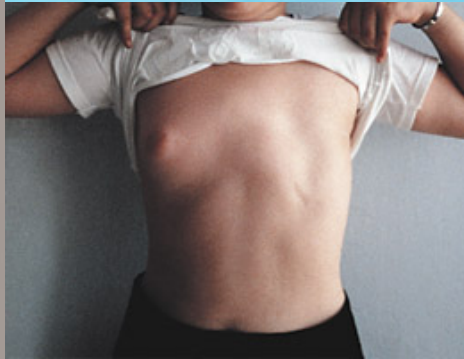### **Arterial Supply of the Breast**

- Lateral (mammary) thoracic a.
- Internal (mammary) thoracic a.
- Intercostal aa.
- Thoracoacromial a.

**Refluxul venos: pe venele superficiale în v. axilaris și profunde în venele intercostale.**

**Inervația – II –VI intercostali, Cutaneous innervationnn. Supraclaviculari Nerves of the Breast**

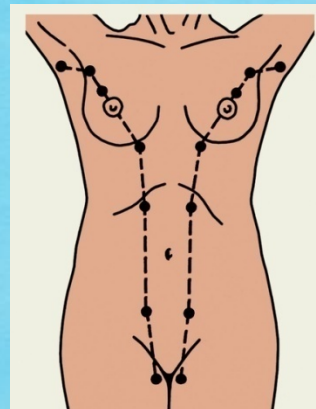
- Medial pectoral n.
- Lateral pectoral n.
- Long thoracic n.



For men the mammary glands has  
1,5x0,5cm.

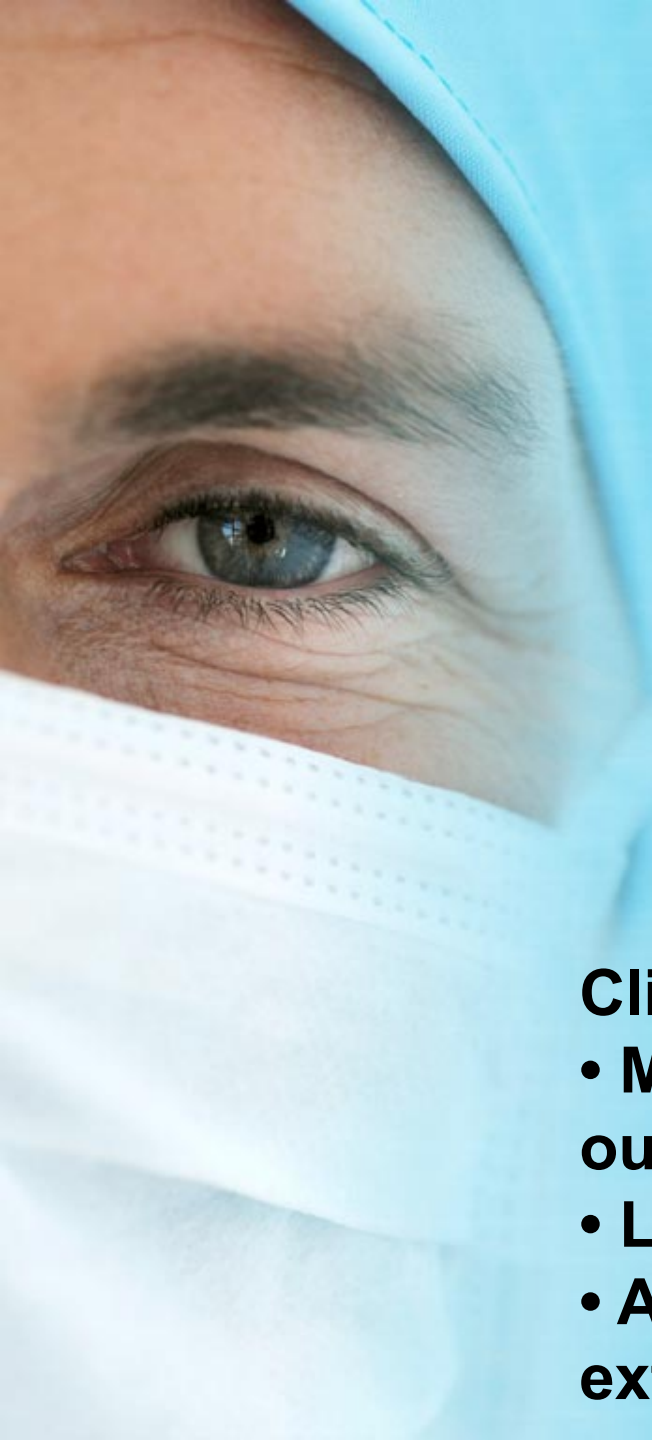## Anomalies

- gynaecomasti-
- amastia
- polymastia
- polytelia
- amastia



- A knowledge of the lymph drainage of the mammary gland can help as part of the diagnosis of mammary disease.
- The gland is subdivided into 4 quadrants (2 medial, 2 lateral). The lymph drainage of the mammary gland is: medial quadrants -- drain medially into lymph nodes along the internal mammary artery.
- lateral quadrants -- drain into the anterior or pectoral group of axillary lymph nodes.
- The anterior group of lymph nodes are easily palpated and should always be part of a general examination in females.





# Four Quadrants of the Breast

- Upper outer (superolateral) quadrant
- Upper inner (superomedial) quadrant
- Lower outer (inferolateral) quadrant
- Lower inner (inferomedial) quadrant

## Clinical Notes on Breast Cancer

- Majority of cancers develop in upper outer quadrant
- Large amount of glandular tissue here
- An axillary tail of breast tissue often extends into axilla



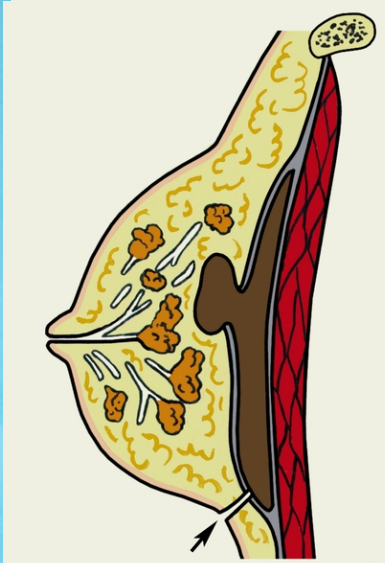
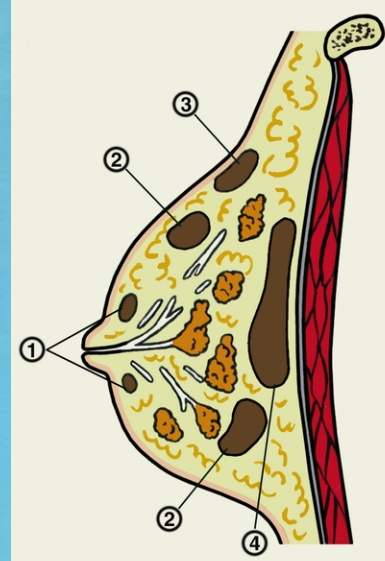
## **Mastitis**

Mastitis is an infection of the breast tissue that results in breast pain, swelling, warmth and redness of the breast.

Mastitis most commonly affects women who are breast-feeding (lactation mastitis), although sometimes this condition can occur in women who aren't breast-feeding.

# Mastitis

- Typs:
- 1 — retromammaris;
- 2 — interstitialis;
- 3 — subareolaris;
- 4 — retromammaris;
- 5 — parenhimatic;
- Radial incizion, submamarincision)







# The thoracic cavity

**Is the space limited by the sternum, ribs, intercostal muscles, thoracic vertebrae and diaphragm.**

**Contains:**

- 1. pleural cavity,**
- 2. pericardiac cavity,**
- 3. mediastinum.**

# The Mediastinum (Interpleural Space)

The **mediastinum** lies between the right and left pleuræ. From the sternum in front to the vertebral column behind, and contains all the thoracic viscera.

It may be divided:

**superior mediastinum** – the upper portion, above the upper level of the pericardium;

**Inferior mediastinum** - a lower portion, below the upper level of the pericardium.

This is subdivided into three parts: **anterior mediastinum** - in front of the pericardium;

**middle mediastinum** that containing the pericardium and its contents;

**posterior mediastinum** behind the pericardium.

The **Superior Mediastinum** lies between the manubrium sterni in front, and the upper thoracic vertebra behind. **It contains:** the origins of the Sternohyoidei and Sternothyreoidei and the lower ends of the Longi colli; the aortic arch; the innominate artery and the thoracic portions of the left common carotid and the left subclavian arteries; the innominate veins and the upper half of the superior vena cava; the left highest intercostal vein; the vagus nerves, cardiac, phrenic, and left recurrent nerves; the trachea, esophagus, and thoracic duct; the remains of the thymus, and some lymph nodes.





# Inferior mediastinum: The Anterior Mediastinum

exists only on the left side where the

left pleura diverges from the mid-sternal line. In front by the sternum, laterally by the pleura, and behind by the pericardium.

It is narrow, above, but widens out a little below.

**It contains:** internal thoracic artery and vein; some connective tissue, lymphatic vessels, two or three anterior mediastinal lymph nodes, and the mediastinal branches of the internal mammary artery.

**The middle Mediastinum contains:**  
the **heart** enclosed in the **pericardium**,  
the **ascending aorta**,  
the lower half of the **superior vena cava** with the **azygos vein** opening into it;  
the bifurcation of **the trachea** and the main two bronchi,  
**the pulmonary artery** dividing into its two branches,  
the **right and left pulmonary veins**,  
the **phrenic nerves**,  
some **bronchial lymph nodes**.



- The **Posterior Mediastinum** is parallel with the vertebral column; it is bounded in front by the pericardium above, and by the posterior surface of the diaphragm below, behind by the vertebral column from the lower border of the fourth to the twelfth thoracic vertebra. It contains the thoracic part of the descending aorta, the azygos and the two hemiazygos veins, the vagus and splanchnic nerves, the esophagus, the thoracic duct, and some lymph nodes.

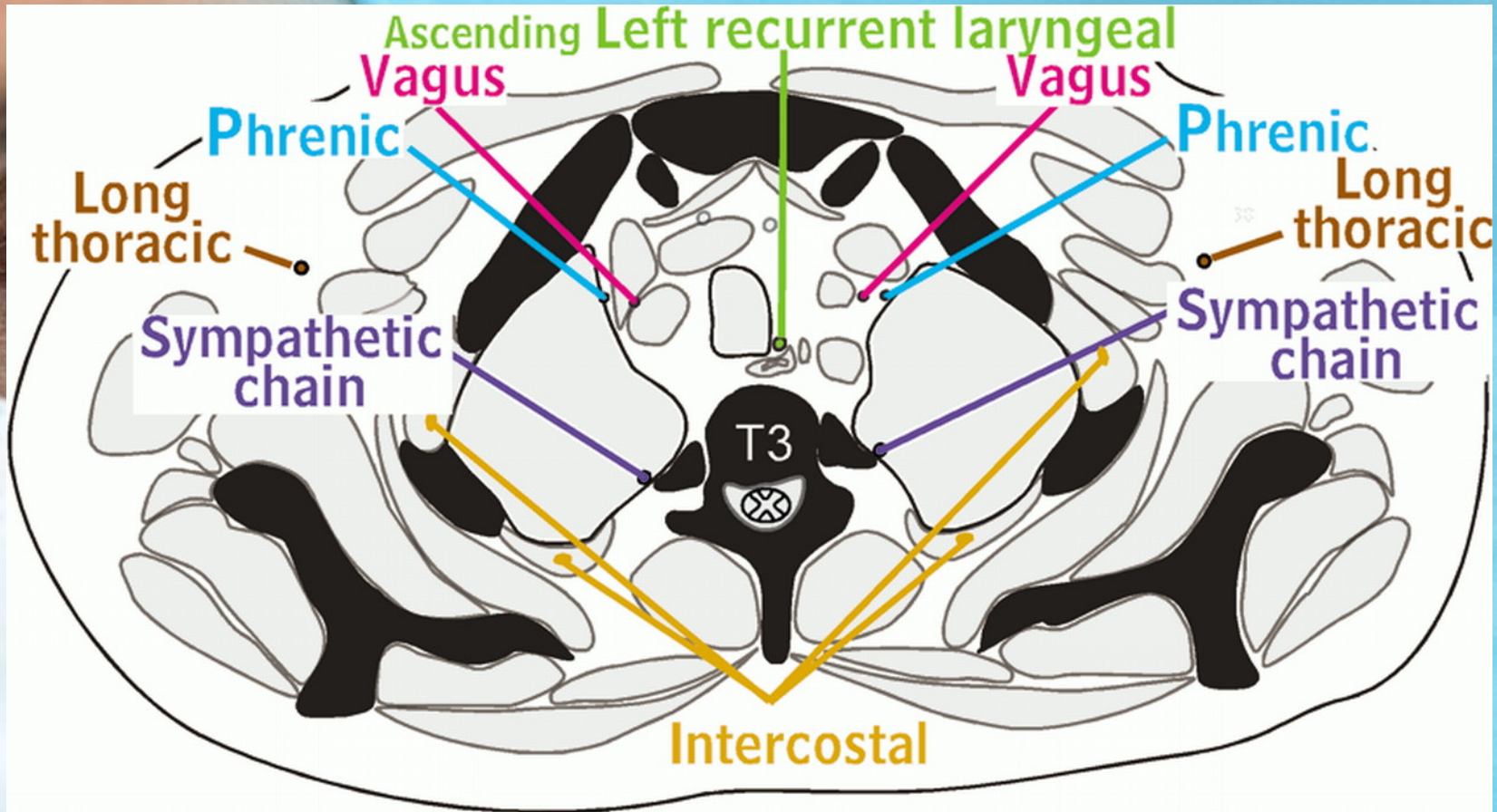




# Hilum

- Opening on the medial surface of the lungs
- Contains:
  - Mainstem bronchi
  - Blood vessels
  - Lymphatics
  - nerves

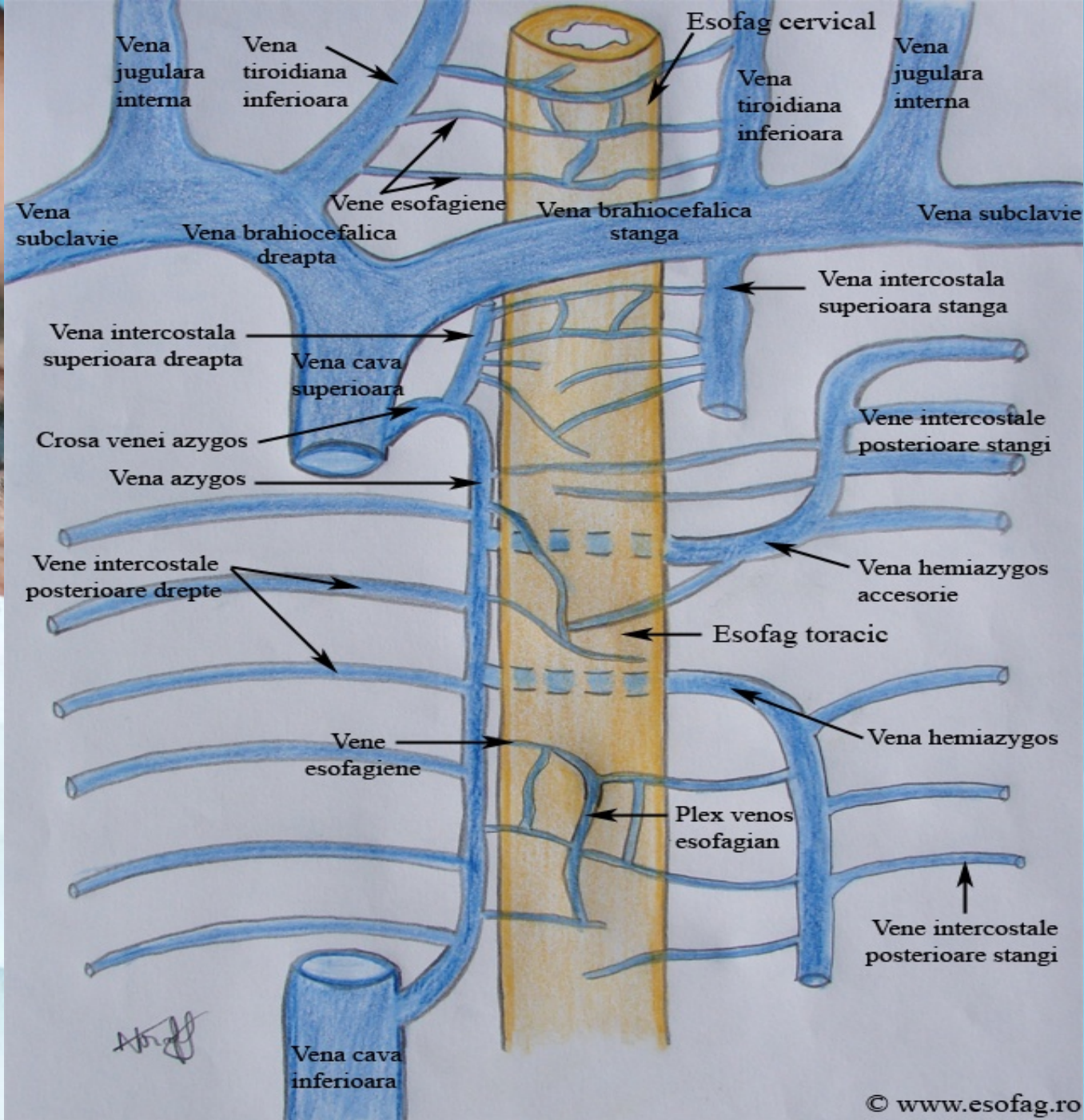
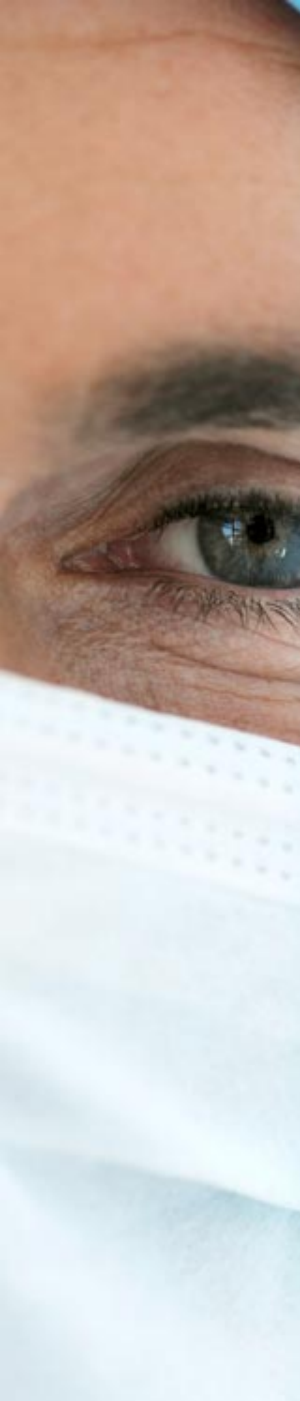Figure 1b. (a, b) Drawings (axial view) illustrate the normal thoracic CT anatomy at the level of the T2 (a) and T3 (b) vertebral bodies.




Aquino S L et al. Radiographics 2001;21:1275-1281

RadioGraphics









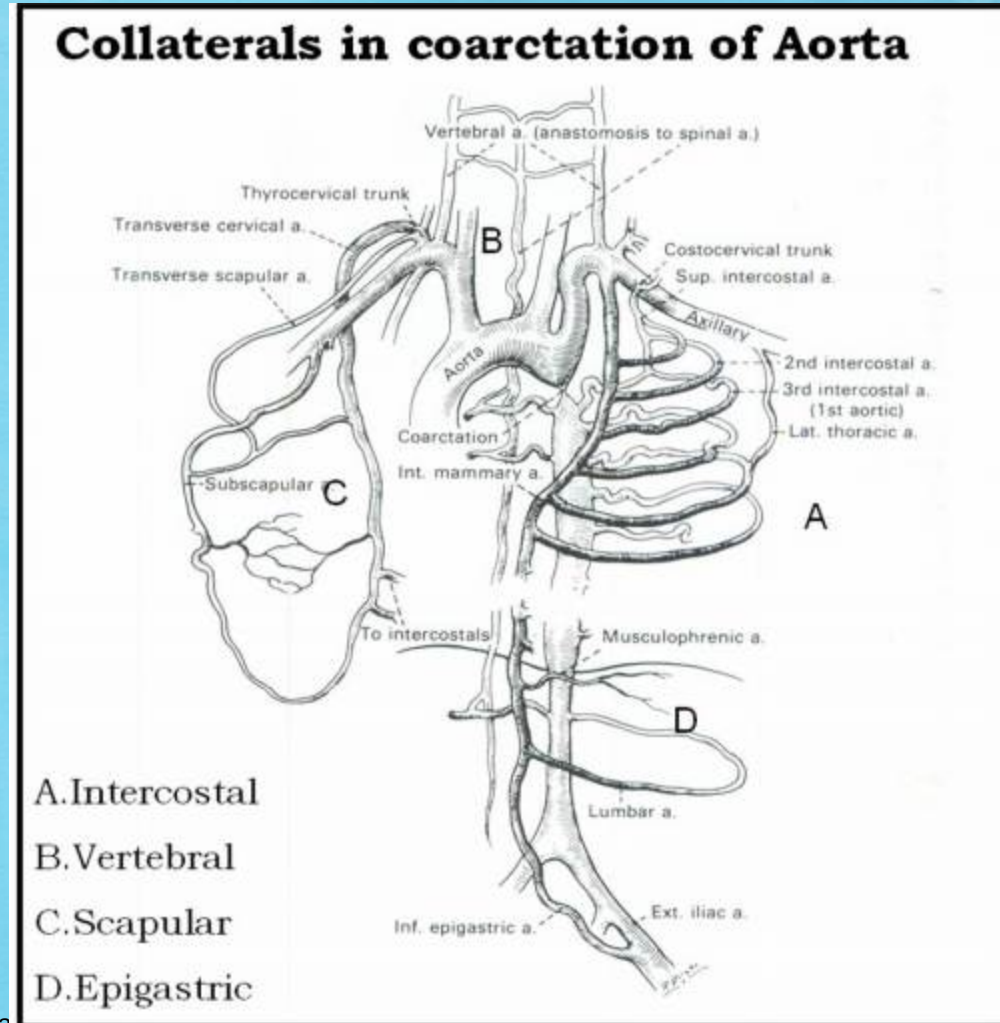
The **ductus arteriosus**, also called the **ductus Botalli**, is a blood vessel connecting the pulmonary artery to the proximal descending aorta. It allows most of the blood from the right ventricle to bypass the fetus's fluid-filled non-functioning lungs. Upon closure at birth, it becomes the **ligamentum arteriosum**. There are two other fetal shunts, the ductus venosus and the foramen ovale.



**Coarctation of the aorta, also called aortic narrowing, is a congenital condition whereby the aorta is narrow, usually in the area where the ductus arteriosus (ligamentum arteriosum after regression) inserts**

# Collaterals in aorta coarctation:

- 1.a. Toracica interna-a. epigastrica superior- a.epigastrica inferior-a.iliaca externa.
- 2.Treuncus tireocervicalis-a. suprascapularis- a.circumflexa scapula-a. Intercostales-aorta toracalis.

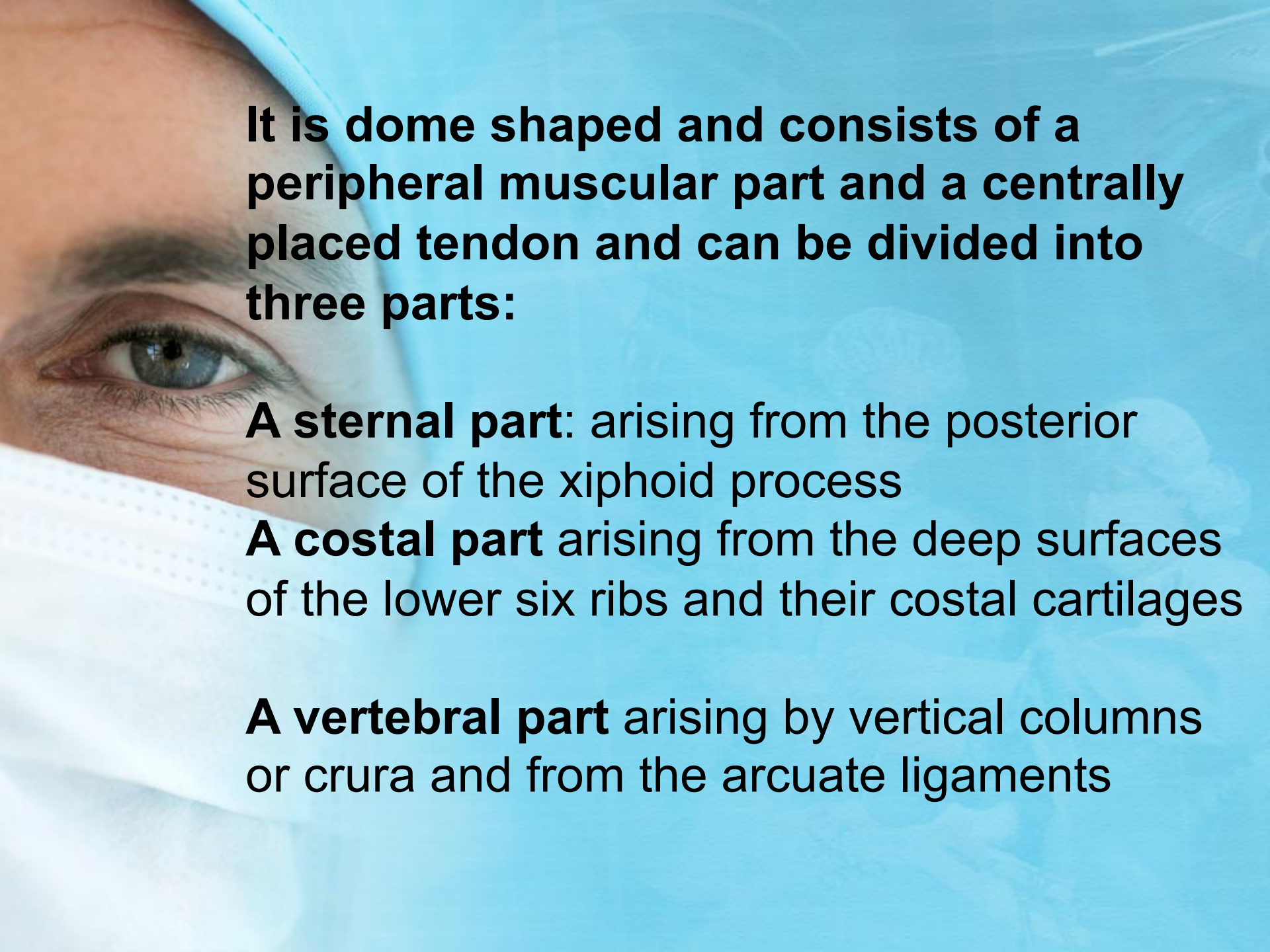






# The diaphragm

- separates the thoracic cavity containing the heart and lungs, from the abdominal cavity,
- respiration: as the diaphragm contracts, the volume of the thoracic cavity increases and air is drawn into the lungs.



**It is dome shaped and consists of a peripheral muscular part and a centrally placed tendon and can be divided into three parts:**

**A sternal part:** arising from the posterior surface of the xiphoid process

**A costal part** arising from the deep surfaces of the lower six ribs and their costal cartilages

**A vertebral part** arising by vertical columns or crura and from the arcuate ligaments

**The right crus** arises from the sides of the bodies of the first three lumbar vertebrae and the intervertebral discs

Some of the muscle fibers of the right crus pass up to the left and surround the esophageal orifice in a slinglike loop. These fibers appear to act as a sphincter and possibly assist in the prevention of regurgitation of the stomach contents into the thoracic part of the esophagus

**The left crus** arises from the sides of the bodies of the first two lumbar vertebrae and the intervertebral disc

Lateral to the crura the diaphragm arises from the **medial and lateral arcuate ligaments**

**The medial arcuate ligament** extends from the side of the body of the second lumbar vertebra to the tip of the transverse process of the first lumbar vertebra.

**The lateral arcuate ligament** extends from the tip of the transverse process of the first lumbar vertebra to the lower border of the 12th rib.

The medial borders of the two crura are connected by a **median arcuate ligament**, which crosses over the anterior surface of the aorta



Openings in the diaphragm

**The inferior vena cava** passes through the central tendon at approximately vertebral level T8

**The esophagus** passes through the muscular part of the diaphragm, just to the left of midline, approximately at vertebral level T10

**The vagus nerves** pass through the diaphragm with the esophagus

**The aorta** passes behind the posterior attachment of the diaphragm at vertebral level T12



# Herniations, weak places

**hiatus aorticus**

**hiatus esophageus**

**foramen vene cave**

**Trigonum sternocostale**

**Morgagni (right)**

**Larrey's (left)**

**Trigonum lumbocostale**

**(Bochdalek's gap),**



# Pleura

- **Serous Membrane**
- **Produces fluid that allows for lubrication**
- **Attaches lung to inner surface of thoracic cage**
- **Failure to function results in difficult painful breathing**





# Pleura and Pleural Cavity

- Mesothelial lining of each hemithorax
- Derived from embryonic coelomic lining

- **Visceral pleura:** lung
- **Parietal pleura:**
  - Costal
  - Diaphragmatic
  - Mediastinal

## Pleural Cavity

- Potential space between visceral & parietal pleura
- Surface tension provides cohesion between lung and thoracic wall

# Pleural Sinuses

The **costodiaphragmatic** recesses are slitlike spaces between the costal and diaphragmatic parietal pleurae.

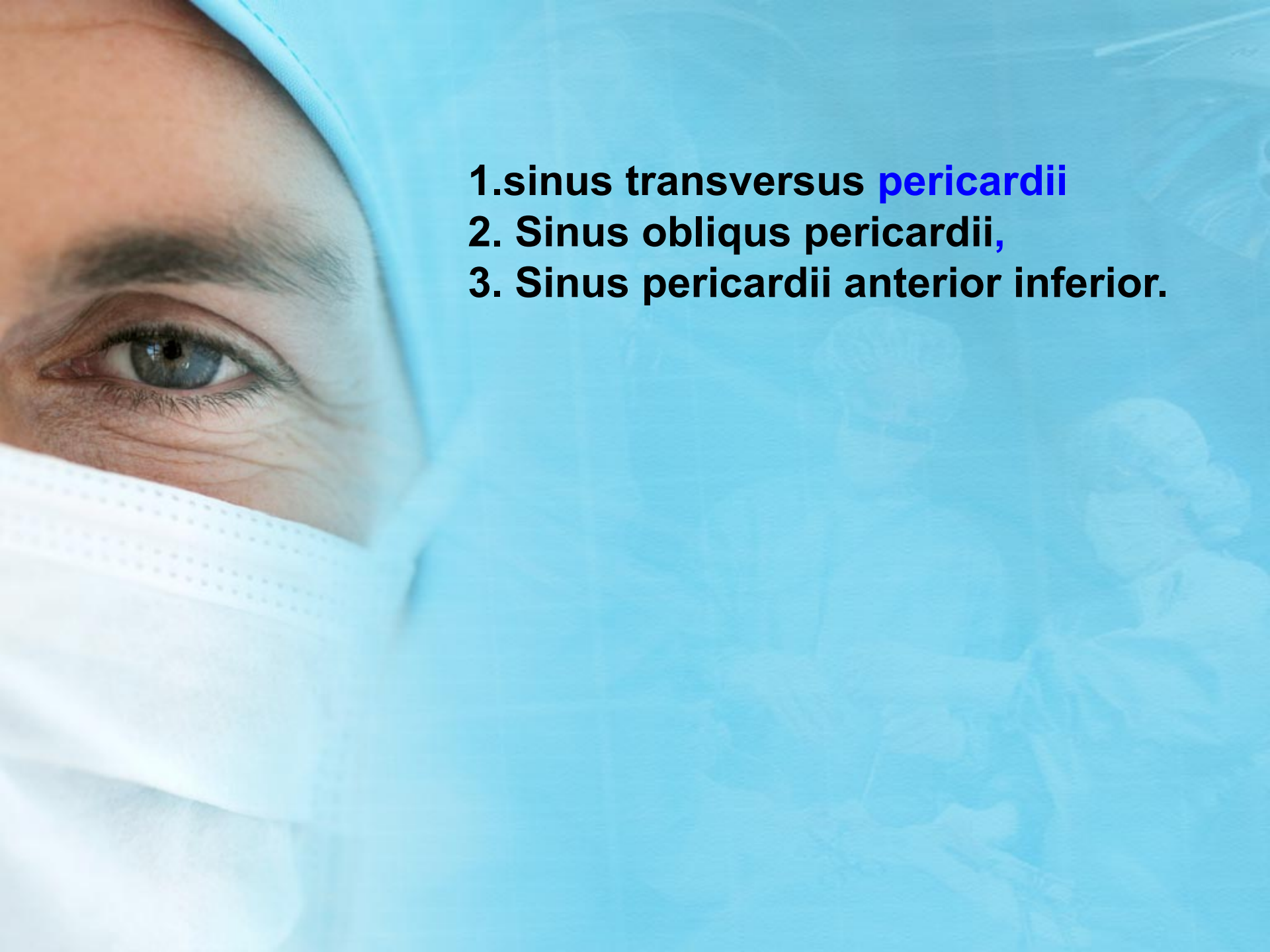
During inspiration, the lower margins of the lungs descend into the recesses. During expiration, the lower margins of the lungs ascend so that the costal and diaphragmatic pleurae come together again.

The **costomediastinal** recesses are situated along the anterior margins of the pleura. They are slitlike spaces between the costal and the mediastinal parietal pleurae. During inspiration and expiration, the anterior borders of the lungs slide in and out of the recesses.

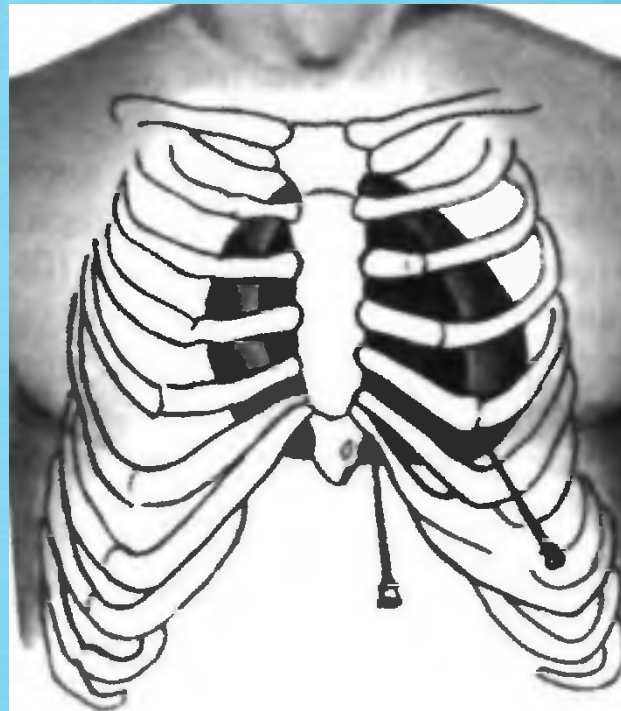
# Pericardium



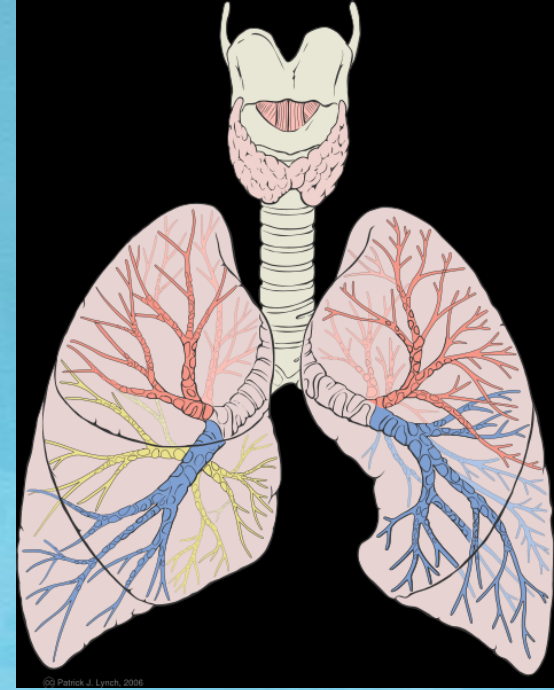


- 
1. sinus transversus **pericardii**
  2. Sinus obliquus pericardii,
  3. Sinus pericardii anterior inferior.

# Pericardiocentesis



# Lungs



- **Pair of Cone-shaped organs**
- **Lie in pleural cavity**
- **Weigh approx 800g**
  - **90% air**
  - **10% tissue**
- **Left lung is narrower**
- **Right lung is shorter**





- Apices-extend 1-2 cm past clavicles
- At end-expiration
  - 6<sup>th</sup> rib – midclavicular
  - 8<sup>th</sup> rib – laterally
- Posteriorly
  - Tops is at 1<sup>st</sup> vertebra
- Inferior border
  - Rises & falls between 9<sup>th</sup> & 12<sup>th</sup> rib



# Lungs

- Each lung is divided into:
  - Lobes: major divisions of the lungs
  - Divided by fissures: narrow clefts or slits
  - Segments: minor divisions of the lungs
  - Secondary lobules: minor divisions of segments

# Lungs

## RIGHT LUNG

3 Lobes  
Upper Middle and Lower

2 Fissures  
Oblique & Horizontal

Segments

Secondary Lobules

## LEFT LUNG

2 Lobes  
Upper and Lower

1 Fissure  
Oblique

Segments

Secondary Lobules



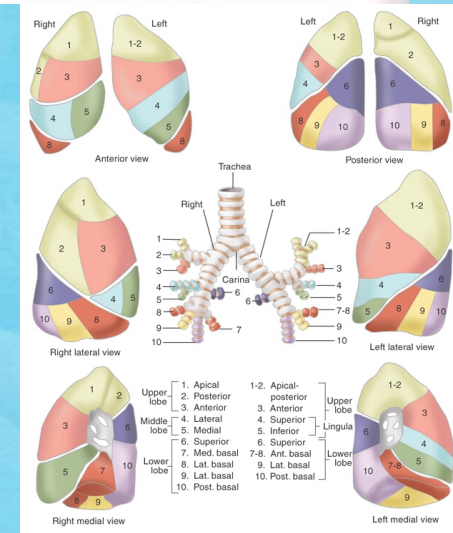
**Table 7-6** ▶▶▶ **Bronchopulmonary Segments\***

Segment	Number	Segment	Number
<b>Right Upper Lobe</b>		<b>Left Upper Lobe</b>	
Apical	1	Upper division	
Posterior	2	Apical-posterior	1 and 2 <sup>†</sup>
Anterior	3	Anterior	3
<b>Right Middle Lobe</b>		<b>Left Lower Lobe</b>	
Lateral	4	Superior lingula	4
Medial	5	Inferior lingula	5
<b>Right Lower Lobe</b>		Superior	6
Superior	6	Anterior basal	7 and 8
Medial basal	7	Lateral basal	9
Anterior basal	8	Posterior basal	10
Lateral basal	9		
Posterior basal	10		

\*The subdivisions of the lung and bronchial tree are fairly constant. Slight variations between right and left sides are noted by combined names and numbers.

<sup>†</sup>**NOTE:** Some authors feel that the left lung should be numbered so that there are eight segments, where the apical-posterior is numbered 1 and the anteromedial is numbered 6.

# Bronchopulmonary Segments





## Pulmonary circulation differs from the systemic circulation in several key aspects

1. PC receives the entire cardiac output during each cardiac cycle, more than any other organ in the body.
2. It maintains low pressure in the face of dramatic increases in cardiac output during normal exertion as well as disease states,
3. It converts the pulsatile blood flow from the right heart into steady-state flow in the capillary bed,
4. PC organizes the vascular network in such a way to optimize the surface area around the alveolar epithelium.

## Branching of the intrapulmonary arteries

### Legend:

- 1- segmentary a.
- 2- subsegmentary a.
- 3- prelobular a.
- 4- lobular a.

$$a_1 < a_2 < a_3 < a_4$$

$$a \rightarrow 90$$

## Pulmonary capillaries

- $D = 5-8$  microns
- Large variability of their origin
- Take part in formation of aero-haematic barrier

## Pulmonary veins (PV)

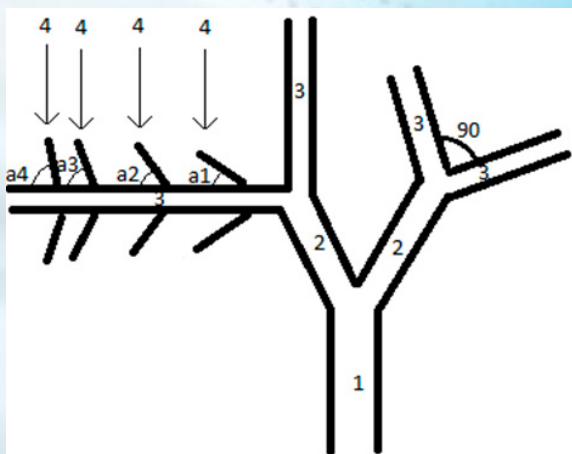
They have arterial non-dependent trajet

They are relatively stright

1 artery  $\rightarrow$  3-4 veins

2 types: intrasegmentary and intersegmentary

Have impact on genesis of the atrial fibrosis





# **Central Venous Catheterization — Subclavian Vein**

Indications - administration of caustic and critical medications as well as allowing sampling of blood and measurement of central venous pressure.

## **Contraindications**


1. infection of the area overlying the target vein and thrombosis of the target vein.
2. fracture of the ipsilateral clavicle or anterior proximal ribs, which can distort the anatomy and make placement difficult.
3. Caution when placing a central venous catheter in coagulopathic patients.

**Important!** The location of the artery (beneath the clavicle) makes application of direct pressure nearly impossible in attempts to control bleeding.

### **Equipment needed**

skin-preparation solution and a drape, lidocaine, sterile gauze, syringes, a scalpel, a catheter, a dilator, several needles, and a guide-wire; sterile gown, sterile gloves, a surgical cap, a mask with a face shield, and drapes to cover the patient's body.



- 
- Technics** Determine the catheter length by referring to the patient's external landmarks: the catheter should reach the junction of the superior vena cava and the right atrium. (range from 4-French catheters for infants to 7-French catheters for adults; 11.5-French catheters may be used for dialysis) . **a** catheter with the fewest number of lumens should be used.
1. Explain the procedure to the patient and obtain written informed consent.
  2. Wear a sterile gown and gloves, a mask with face shield, and a surgical cap.
  3. Place the patient in the 15-degree Trendelenburg position, which will engorge the vein. (place a rolled towel under the spine to help identify the patient's external landmarks, turning the head to opposite side)
  4. Scrub the area thoroughly with antiseptic. Drape the area.



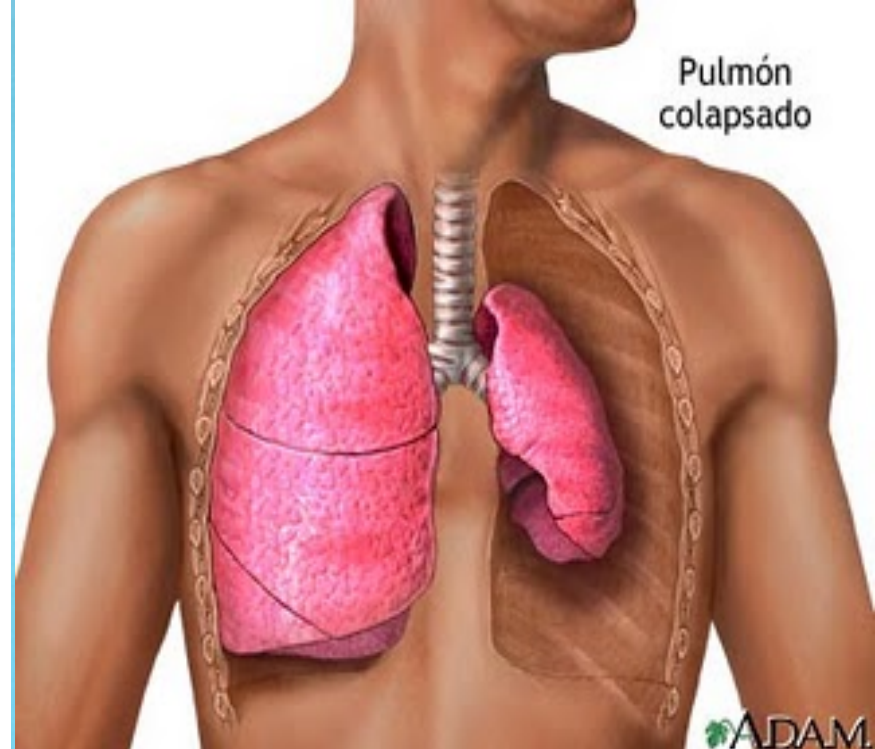
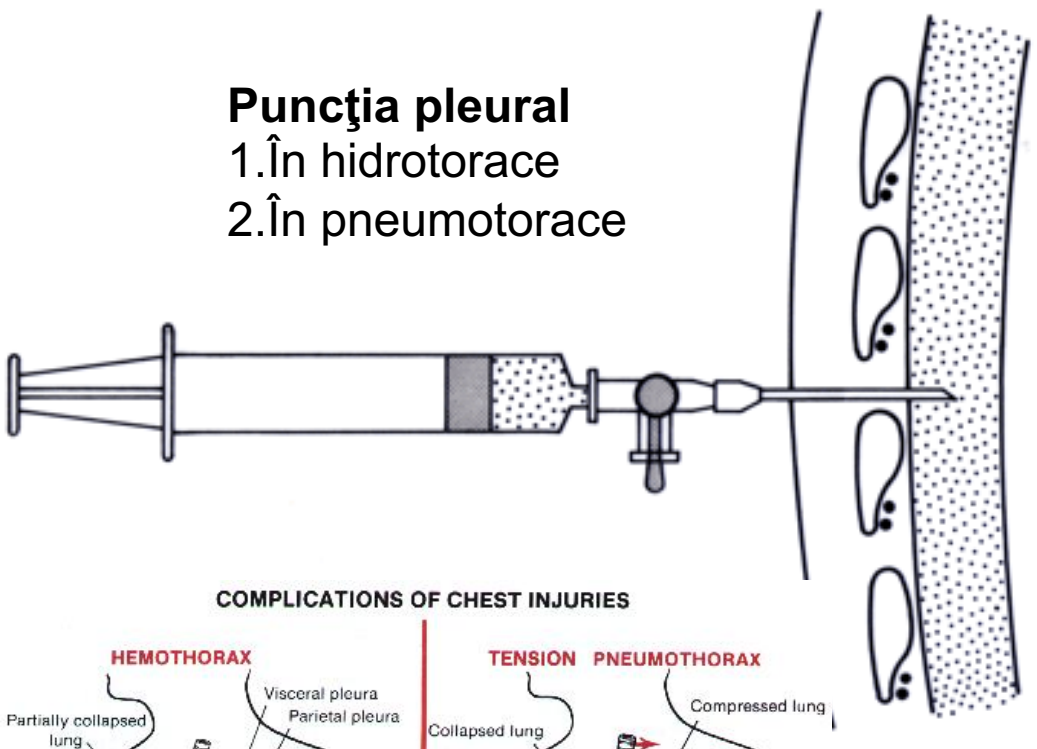
- 5. identify anatomic landmarks, beginning with the middle third of the clavicle.
- 6. Typically, the point of insertion is 2 cm lateral to and 2 cm caudal to the middle third of the clavicle.
- 7. Local anesthesia with 1 to 2 ml of 1 percent lidocaine or equivalent should be used in this area.

# Pleura

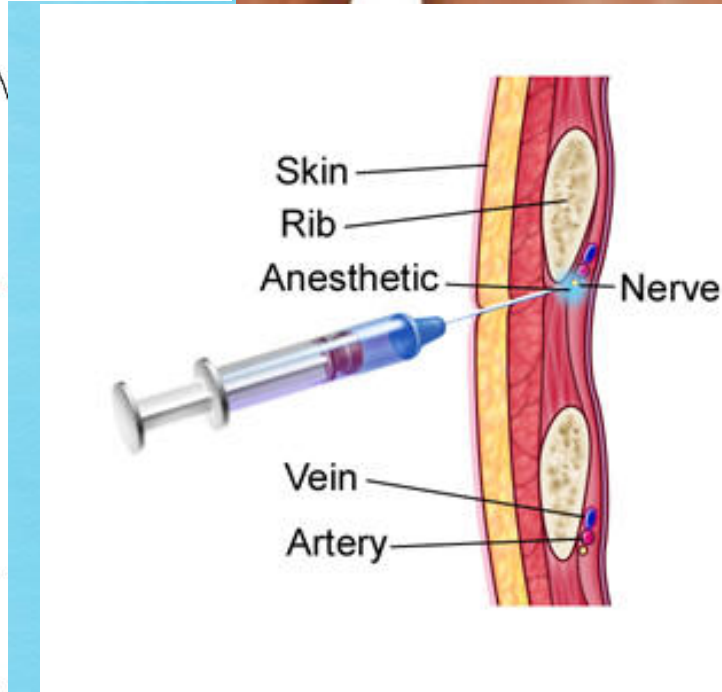
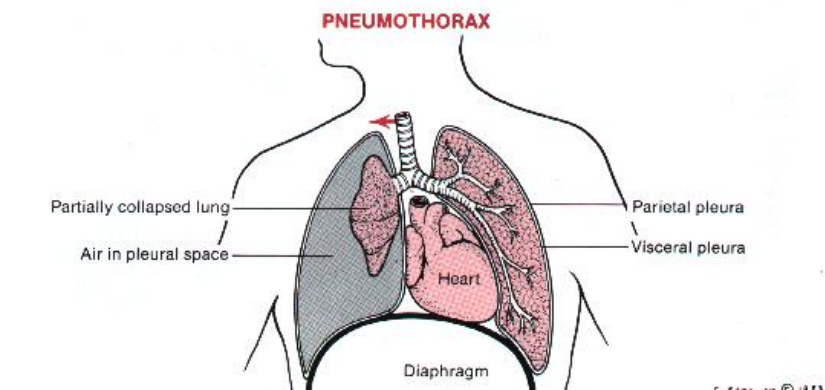
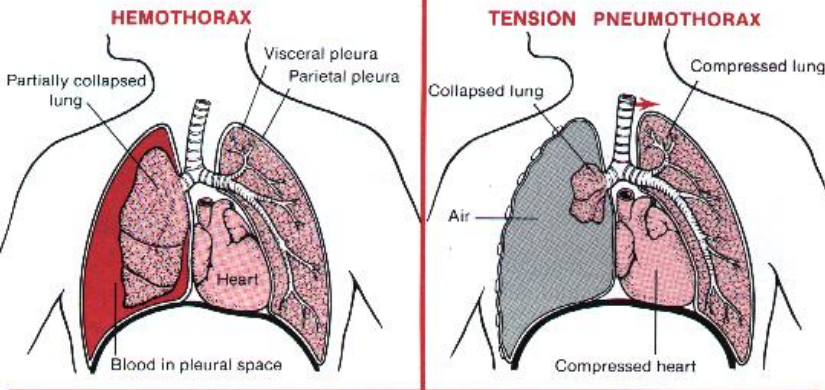


# Puncția pleural

- 1. În hidrotorace
- 2. În pneumotorace

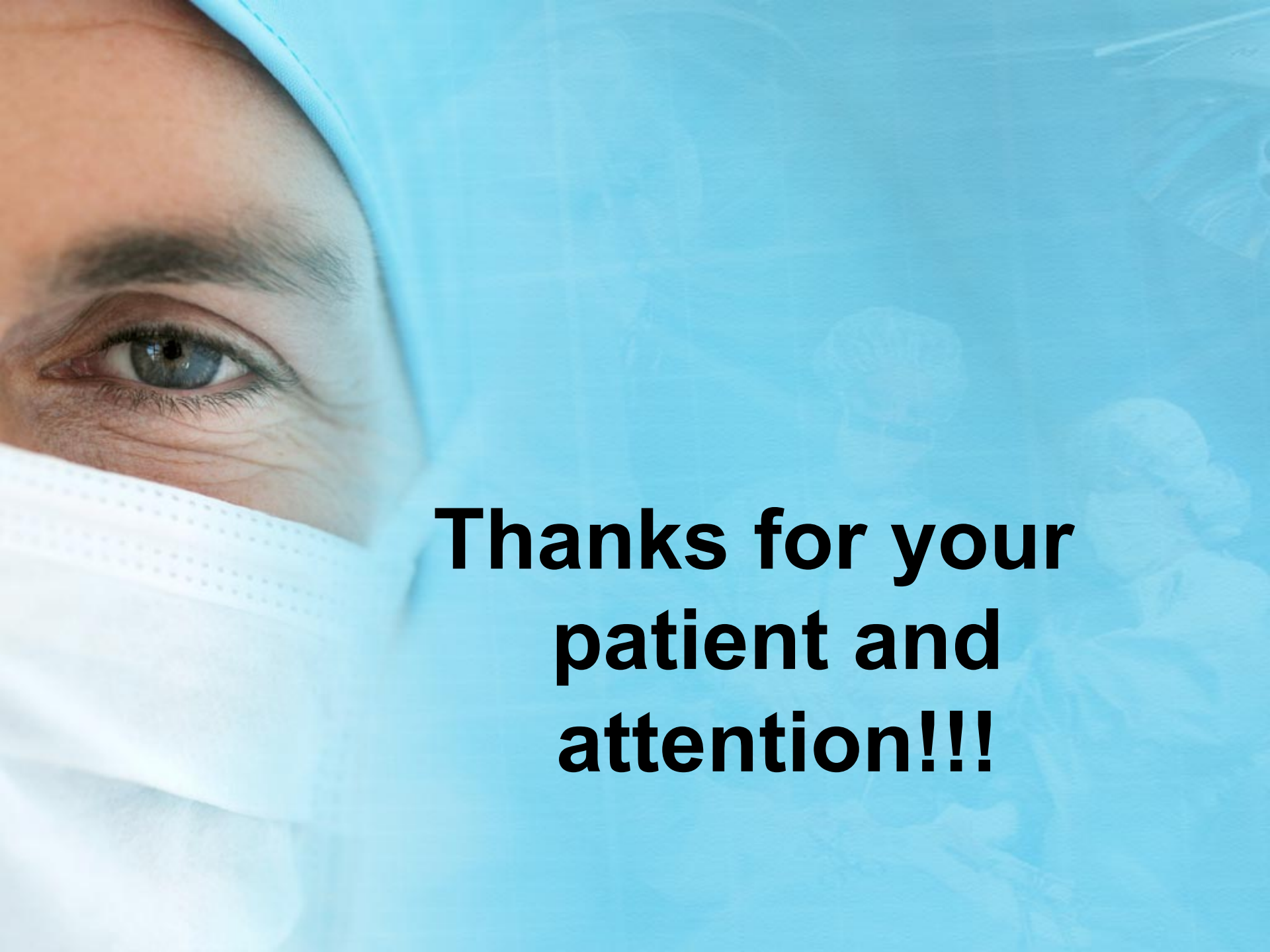

## COMPLICATIONS OF CHEST INJURIES



Blocajul n. intercostal.





**Thanks for your  
patient and  
attention!!!**